

Tumor Lysis Syndrome in a Post-Operated Case of Metastatic Thyroid Carcinoma

Rajeev K^{1*} and Sumit K²

¹Consultant In-charge of Intensive Care Unit and Cardiac Anesthesia division, Vivekananda Polyclinic and Institute of Medical Sciences, Lucknow, India

²Assistant Professor, Department of Anesthesiology and critical care medicine, Dr. Ram Manohar Lohia Institute of Medical Sciences, Lucknow, India

***Corresponding author:** Rajeev K, Consultant In-charge of Intensive Care Unit and Cardiac Anesthesia division, Vivekananda Polyclinic and Institute of Medical Sciences, Lucknow-226007, India, Tel: 918004019936, E-mail: dr.rajeevkumar2@gmail.com

Citation: Rajeev K, Sumit K (2019) Tumor Lysis Syndrome in a Post-Operated Case of Metastatic Thyroid Carcinoma. J Anaesth Ther 2: 103

Abstract

Tumor Lysis Syndrome (TLS) is an oncological emergency which can lead to significant morbidity and mortality. Early recognition and treatment are the keys to limit the sequelae of TLS. Diagnosis may be delayed because this may be present the first symptom of underlying malignancy. Therefore, it is imperative that all clinicians are familiar with this syndrome to assure timely recognition. In this report, we describe the case of TLS in thyroid malignancy after radioiodine ablation therapy.

Keywords: Acute kidney Injury; Arrhythmias; Leukocytosis; Radio-iodine Therapy; Thyroid carcinoma

Introduction

Approximately 90% of thyroid cancers cases are well differentiated, and are classified as papillary thyroid carcinoma (PTC) or follicular thyroid carcinoma (FTC) based on the predominant histology [1]. Among all PTC variants, follicular variant of papillary thyroid carcinoma (FV-PTC) is most common subtype of PTC [2]. FV-PTC clinical behavior is unique and represents an intermediate entity with clinical features that are between classical PTC and FTC. Pulmonary metastases and bone metastases have been reported in FV-PTC cases [3]. The most common manifestation of bone metastases include pain, fracture and spinal cord compression associated with lesions in the axial skeleton. Despite the variations in clinical behavior, after total thyroidectomy and postoperative radioactive iodine ablation therapy, the long term outcome of these patients remains similar to classical PTC. Use of radioactive iodine is generally safe with some potential side effects, classified as early and late complications. Early complications include gastrointestinal symptoms, radiation thyroiditis, sialadenitis/xerostomia, bone marrow suppression, gonadal damage, and nasolacrimal duct obstruction. The late complications include secondary cancer, pulmonary fibrosis, permanent bone marrow suppression, and genetic effects.

We present a case of a patient diagnosed with metastatic follicular variant of papillary thyroid carcinoma who developed tumor lysis syndrome after initiation of radioiodine therapy, which is a rare manifestation of this disease.

Case Presentation

60 years old female patient presented to our hospital with swelling in neck with progressive increase in size for 2 years and history of right shoulder pain and swelling for 6 months, with gradual reduction in range of movements. MRI revealed metastasis involving the right scapular blade and spine. Fine Needle Aspiration Cytology from neck swelling and shoulder demonstrated follicular neoplasm. Patient was diagnosed as metastatic Follicular Thyroid Carcinoma on the basis of history, examination and FNAC report. Total thyroidectomy was performed and histopathology report confirmed follicular variant of papillary thyroid carcinoma. Immediate postoperative period was uneventful. Patient was referred to nuclear medicine department for radioiodine ablation therapy. A whole body radioiodine scan (WBRI) was done, which was suggestive of multiple skeletal metastasis and residual in neck (Figure 1). Base line laboratory investigations (pre radioiodine ablation therapy) were within normal limits. She was treated with 150mCi of I¹³¹ and admitted in isolation ward. Next day patient developed nausea and 2 episodes of non-projectile vomiting.

Three days later, patient was confused and irritable; vitals were stable except decreased urine output. Metabolic encephalopathy was suspected but CT head, EEG and CSF findings were normal. Blood investigations (Table 1) demonstrated deranged Serum creatinine (4.6 mg/dl), Serum BUN(117 mg/dl), Total Leukocyte Count (94,700/mm³), Differential Leukocyte Count (N-94, L-06) and electrolyte (Na⁺- 126, K⁺- 6.0). ABG report, pH - 7.32, PCO₂ - 32.6, Na⁺ - 136, K⁺ - 6.22, HCO₃⁻ - 16.6, AG - 18. Medical management for hyperkalemia was given, and patient shifted to dialysis unit for sustained low efficiency dialysis (SLED).

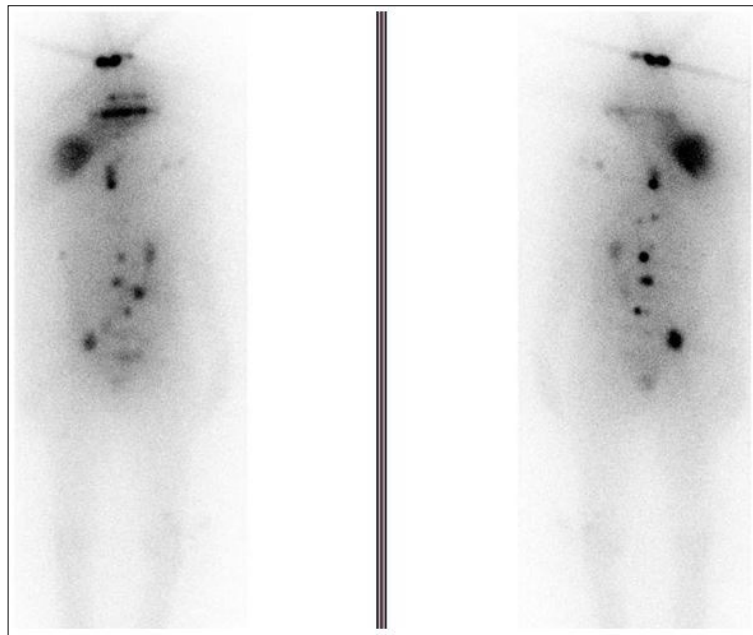


Figure 1: Whole body radioiodine (WBRI) scan

Parameters	Pre-operative	Before RIA	D-3 of RIA	ICU D-1	ICU D-2	ICU D-3	ICU D-4
Hemoglobin (gm/dl)	11.0	10.0	8.1	7.6	7.6	7.2	7.2
TLC (x 10 ³ cells/ul)	8.2	7.8	94.7	67.1	88.5	100.8	87.5
Platelet count	180	170	207	190	188	149	156
S. BUN (mg/dl)	20	24	117	84	96	112	108
S. Creatinine (mg/dl)	1.1	1.2	4.6	3.4	3.8	3.5	3.6
S. Uric acid (mg/dl)	-	-	-	20.5	22.0	16.0	18.5
S. Sodium (mmol/l)	137	135	126	141	129	135	134
S. Potassium (mmol/l)	4.2	4.0	6.0	3.0	5.4	4.2	5.4
S. Calcium (mg/dl)	8.9	8.5	7.0	6.8	6.5	7.0	6.3
S. Phosphorus (mg/dl)	-	-	-	9.6	10.0	10.5	11.2
S. Bilirubin (mg/dl)	0.65	0.66	0.6	3.9	3.1	2.5	-
AST (u/l)	22	24	36	171	110	90	-
ALT (u/l)	15	15	18	44	52	58	-
ALP (u/l)	44	40	77	44	44	42	-
LDH (u/l)	-	-	-	1175	976	553	875
Procalcitonoin (ng/ml)	-	-	0.20	-	0.50	2.46	8.64
Lactate (mg/dl)	-	-	14	20	24	28	54

TLC: total leucocyte count; BUN: blood urea nitrogen; AST: alanine aminotransferase; ALT: aspartate aminotransferase; ALP: alkaline phosphate; LDH: lactate dehydrogenase

Table 1: Laboratory values

After dialysis patient's GCS improved but next day again became confused and developed hypotension (SBP- 85 mmHg), tachypnea, and admitted in the Intensive Care Unit. At the time of admission, Acute Physiology And Chronic Health Evaluation II (APACHE II) was 32 and The Sequential Organ Failure Assessment (SOFA) score was 9. ABG at admission, pH - 7.29, PCO₂ - 30, Na⁺- 140, K⁺- 3.50, HCO₃⁻ - 14.6, AG - 18. Patient put on controlled oxygen therapy with strict vital monitoring. Noninvasive and Invasive monitoring (CVP and Arterial line) were attached, vasopressor (Noradrenaline@ 0.05 microgram/kg/min)) was started after initial unresponsive fluid therapy. Blood culture and urine culture were sent and intravenous antimicrobial therapy was started. Screening ultrasound of lung and contractility of heart was normal. Inferior vena-cava (IVC) diameter was 1.7 cm but no respiratory variation

noted. In ICU course of Day-3, patient developed respiratory distress and after intubation put on mechanical ventilator, and vasopressor support also increased (noradrenaline @0.1 microgram/kg/min). CRRT started in view of severe metabolic acidosis, hyperkalemia along with decreased urine output. Even after increasing the vasopressor dose, patient's hemodynamics were not stable. Ventilator support was increased in the form of Fio2 & PEEP. There was refractory acidosis, hyperkalemia and hypoxia which culminated to cardiac arrest. ABG pH - 7.13, PO2 - 56.4, PCO2 - 30, Na/K - 138/6.84, HCO₃ - 6.6, BE - (-) 18.6, AG - 25.3. CPR was done as per ACLS guidelines but patient could not be revived.

Discussion

The patient in this case demonstrated atypical presentation of metastatic follicular variant of papillary thyroid carcinoma after radioiodine therapy. Pre-operative and pre-RIA blood investigations (Table 1) were normal and after RIA therapy, nausea, vomiting and anorexia are common. Clinical finding like confusion, irritability and decreased urine output along with laboratory findings - increased serum creatinine, blood urea nitrogen, leukocyte count and deranged electrolytes raised the suspicion of various differential diagnoses (Table 2).

Criteria	Metabolic Encephalopathy	Leukemoid Reaction	Sepsis	Tumor Lysis Syndrome
Definition	Defined as a diffuse cerebral dysfunction, typically manifesting as changes in cortical functions and as disorders of consciousness, ranging from confusion to coma [12]	Leucocyte count >50,000 cells/ μ L, caused by reactive cause outside the bone marrow [15]	Defined as life threatening organ dysfunction caused by a dys-regulated host response to infection [16]	Tumor lysis syndrome is a combination of metabolic and electrolyte abnormalities that occurs in rapidly proliferating neoplasm after initiation of anticancer therapy
Etiology	The most frequent causes are hypoxia, ischemia, systemic disease, and toxic agents [13,14]	Major causes are severe infections, intoxication, malignancies, severe haemorrhage or acute haemolysis	Bacterial infections are the most common cause followed by fungal infections and rarely viral infections	Most commonly in non-Hodgkin's lymphoma, acute leukemia, less commonly in chronic leukemia and rarely in solid malignancies [17,18,19]
Diagnosis	Based on clinical features and ABG, laboratory analysis of blood biochemistry, EEG, SSEP, and imaging methods (MSCT and MRI)	Diagnosed after the exclusion of haematological malignancy	Based on clinical criteria, appropriate microbiological cultures, sepsis markers, laboratory tests and radiological imaging	The CairoBishop criteria for the diagnosis of laboratory and clinical TLS [8]

ABG: arterial blood gas analysis; EEG: electroencephalography; SSEP: somatosensory evoked potential; MSCT: multi slice spiral computed tomography; MRI: magnetic resonance imaging

Table 2: Differential Diagnosis

Leukocytosis exceeding 50,000 WBC/mm³ raised the suspicion of leukemoid reaction, which is a physiological response to stress or infection. Peripheral blood smear and serum leukocyte alkaline phosphatase was in support of leukemoid reaction but could not explain AKI and electrolyte imbalance. Sepsis was also suspected but initial procalcitonin level and lactate was not significant raised. Blood and urine culture reports were awaited. Metabolic encephalopathy could not be ruled out even if CT head, CSF and EEG were normal, because there was derangement in laboratory parameters.

The patient had oliguric renal failure and characteristic laboratory abnormalities including hyperkalemia, hyperuricemia, and hyperphosphatemia along with hypocalcemia in setting of metastatic disease. The risk factors for TLS (Table 3) like metastatic infiltration of bone, dehydration and hypotension were present in our patient [4]. Pathophysiology of tumor lysis syndrome is characterized by an extensive breakdown of tumor cells releasing intracellular contents into the bloodstream, leading to hyperuricemia, hyperphosphatemia, metabolic acidosis and hyperkalemia [6]. These metabolic disturbances may in turn cause acute kidney injury (AKI), hypocalcaemia, seizures, cardiac arrhythmias, and death. TLS is considerably more common in hematological malignancies such as acute leukaemia and Burkitt's lymphoma but it is also reported in solid tumors [5,7]. Most authors and oncologic societies define TLS according to the laboratory and clinical criteria proposed by Cairo and Bishop (Table 4) [8].

Cancer related risk factors	Patient related risk factors
Large burden of tumor	Pre-existing nephropathy
Neoplastic infiltration of the bone marrow, liver, spleen, kidney	Hyperuricemia Exogenous potassium or phosphorus intake
Tumor with high mitotic rate	Hypotension
Tumor high chemosensitive	Dehydration
Hematologic malignancy	Nephrotoxins (drugs, contrast)

Table 3: Risk factors for developing a tumor lysis syndrome [6]

Cairo- Bishop criteria		
Laboratory TLS ≥ 2 of the following		Clinical TLS = Lab TLS plus ≥ 1 of the following
Uric acid	≥ 8 mg/dl	Acute kidney injury
Potassium	≥ 6.0 m mol/l	Seizure
Phosphate	≥ 6.5 mg/dl	Arrhythmias
Calcium	≤ 7 mg/dl	Sudden death

Laboratory alterations should be measured within the same 24 hours and must occur within 3 days before and 7 days after chemotherapy. TLS - tumor lysis syndrome

Table 4: Criteria for laboratory and clinical tumor lysis syndrome as defined by Cairo-Bishop [5]

The prevention of disease is more cost effective than the treatment of an established disease, therefore before the start of cancer targeted therapy, rule out any underlying kidney disease and possible hypovolemia. All patients at risk of TLS should be actively hydrated to maintain urine output of at least 2 ml/kg/hr to minimize risk of AKI [9]. In patient with underlying acute kidney injury or cardiac dysfunction, intravenous hydration can lead potentially dangerous fluid overload and pulmonary edema. In this occasion, close monitoring and follow-up are mandatory. Loop diuretics can be used if patient develops signs of fluid overload. Hypouricemic agents should be started at least 24 to 48 hour prior to start chemotherapy or radiotherapy to reduce the risk of uric acid nephropathy. Urine alkalinization is another way to managing patients at risk of TLS, because alkaline urine pH promotes uric acid solubility and its removal [10]. However, alkalinization of urine is no longer routinely recommended because it may be associated with metabolic acidosis and calcium phosphate precipitation [5,11].

We conclude that this patient, a known case of FV-PTC was operated and developed TLS after radioiodine ablation therapy. We believe that TLS is difficult to diagnose because of its bizarre clinical presentation and associated with poor outcome. While managing patients of bulky tumor with metastasis such as treatment with radiotherapy or chemotherapy involving cell death, high level of suspicion should be made if they develop concurrent renal dysfunction.

References

- Jossart GH, Clark OH (1994) Well-differentiated thyroid cancer. *Curr Probl Surg* 31: 933-1012.
- Zidan J, Karen D, Stein M, Rosenblatt E, Basher W, et al. (2003) Pure versus follicular variant of papillary thyroid carcinoma: clinical features, prognostic factors, treatment, and survival. *Cancer* 97: 1181-5.
- Liu L, Venkataraman G, Salhadar A (2007) Follicular variant of papillary thyroid carcinoma with unusual late metastasis to the mandible and the scapula. *Pathol Int* 57: 296-8.
- Howard SC, Jones DP, Pui CH (2011) The tumor lysis syndrome. *N Engl J Med* 364: 1844-54.
- Hochberg J, Cairo MS (2008) Tumor lysis syndrome: current perspective. *Haematologica* 93: 9-13.
- Wilson FP, Berns JS (2012) Onco-nephrology: tumor lysis syndrome. *Clin J Am Soc Nephrol* 7: 1730-9.
- Gemici C (2006) Tumourlysis syndrome in solid tumours. *Clin Oncol* 18: 773-80.
- Cairo MS, Bishop M (2004) Tumourlysis syndrome: new therapeutic strategies and classification. *Br J Haematol* 127: 3-11.
- Coiffier B, Altman A, Pui CH, Younes A, Cairo MS (2008) Guidelines for the management of pediatric and adult tumor lysis syndrome: an evidence-based review. *J Clin Oncol* 26: 2767-78.
- Conger JD, Falk SA (1977) Intrarenal dynamics in the pathogenesis and prevention of acute urate nephropathy. *J Clin Invest* 59: 786-93.
- Wilson FP, Berns JS (2012) Onco-nephrology: Tumor Lysis syndrome. *Clin J Am Soc Nephrol* 7: 1730-9.
- Angel MJ, Chein R, Young GB (2008) Metabolic Encephalopathies. *Clin Neurol* 60: 115-66.
- Supanc V, Vargek-Solter V, Demarin V (2003) Metabolic encephalopathy. *Acta Clin Croat* 42: 351-7.
- Sanap MN, Worthley LI (2002) Neurologic complication of critical illness: Part I. Altered states of consciousness and metabolic encephalopathies. *Crit Care Resusc* 4: 119-32
- Nimieri HS, Makoni SN, Madziwa FH, Nemiary DS (2003) Leukemoid reaction response to chemotherapy and radiotherapy in a patient with cervical carcinoma. *Ann Hematol* 82: 316-7.
- Singer M, Deutschman CS, Seymour CW, Shankar-Hari M, Annane D, et al. (2016) The third international Consensus Definitions for Sepsis and Septic Shock (Sepsis-3). *JAMA* 315: 801-10.
- Busakhala W, Joshi MD, Abinya NO, Amayo A, Abwao HO (2007) Incidence of chemotherapy-related tumour lysis syndrome at Kenyatta National Hospital, Nairobi. *East Afr Med J* 84: 100-9.
- Cairo MS, Thompson S, Stern L, Sherman S (2012) Incidence of treatment-related, laboratory and clinical tumor lysis syndrome. *Blood* 120: 238.
- Mirzakhimov AE, Ali AM, Khan M, Barbaryan A (2014) Tumor lysis syndrome in solid tumors: an up to date review of the literature. *Rare Tumors* 6: 5389.