

Surgical Management of Bilateral Bronchiectasis: Should we Operate on Both Sides?

M Lakranbi^{1,3}, F Lamouime^{1*}, M Rhaouti¹, H Harmouchi¹, L Belliraj¹, FZ ammori¹, S Zouiten²,
M Serraj^{2,3}, Y Ouadnoui^{1,3} and M Smahi^{1,3}

¹Department of Thoracic surgery, University Hospital Hassan II-Fes, Morocco

²Department of pulmonology, University Hospital Hassan II-Fes, Morocco

³Faculty of Medicine and Pharmacy, Sidi Mohamed Ben Abdellah University, Fes, Morocco

***Corresponding author:** F Lamouime, Department of thoracic surgery, CHU Hassan II of Fes, Morocco, Tel: +212674029977, E-mail: lamaouime.fatimaezzahrae@gmail.com

Citation: M Lakranbi, F Lamouime, M Rhaouti, H Harmouchi, L Belliraj, et al. (2020) Surgical Management of Bilateral Bronchiectasis: Should we Operate on Both Sides?. J Surg Sci Oper Care 2: 101

Article history: Received: 20 February 2020, Accepted: 10 March 2020, Published: 19 March 2020

Summary

Introduction: Bronchiectasies is defined by permanent and irreversible dilation of the caliber of the bronchi with an impairment of their mucociliary function. surgical treatment remains an attractive alternative to the failure of medical care.

Through this retrospective study and a review of literature we reported our results of surgery in bilateral sequelae bronchiectasis by comparing the clinical courses also the respiratory functional exploration of patients who were operated on both sides compared to this who had had only one surgical treatment.

Material and Methods: We conducted a retrospective, descriptive and analytical study in the thoracic surgery department of Chu Hassan II Fez Concerning 10 patients operated for bilateral bronchiectasis during the period from January 2016 to December 2019

Results: There were 3 men and 7 women with an average age of 39,9 years , forty percent (60%) will be treated for pulmonary tuberculosis and declared cured chronic bronchorrhea predominantly hemoptysis 50% were the main symptoms on the CT scan plan we noted the predominance of cylindrical bronchiectasis which was present in 6 patients 60% Bronchial fibroscopy performed in all patients which showed a 1st degree inflammatory aspect of the bronchi. The approach was a conservative posterolateral thoracotomy in all cases. The procedures performed were a lobectomy in 90% of the patients the evolution was favorable for all patients with disappearance of the symptomatology in 60% of patients and no case of death was noted to that date.

Conclusion: Surgical treatment for bronchiectasis remains an interesting alternative, with low morbidity and mortality , which should be offered early to patients in the event of a complication of DDB or a deterioration in the quality of life that persists despite well conducted medical treatment.

Keywords: Bilateral Bronchial Dilatation ; Surgery ; Spirometry ; Evolution

Introduction

Bronchiectasis is defined by a permanent and irreversible dilation of the caliber of the bronchi with an alteration of their mucociliary function [1-3]. The treatment is mainly medical. As a last resort, and faced with the failure of well-managed medical care, there are well-coded surgical indications allowing to prevent the evolution and preserve the quality of life in patients with a bilateral localized form [4,5,11]. The objective of our study and to report our results of surgery in bilateral bronchiectasis by comparing the clinical and functional respiratory evolution of patients who have been operated on both sides compared to those who have benefited from a single surgical treatment.

Material and Methods

This is a comparative and analytical retrospective study, concerning patients operated on for bilateral bronchial dilations in the thoracic surgery department of the university hospital Hassan II Fez over a period of 4 years ranging from 01-01 2016 to 31-12-2019. During this period, 10 cases of bilateral bronchial dilatation were operated; 5 on one side and 5 on two sides, and we analyzed the clinical and respiratory function of the two groups.

Results

Groups A consisted of 5 patients operated for bilateral bronchial dilation who underwent complete unilateral resection or unilateral resection on the predominant lesion Group B consisted of 5 patients operated for bilateral bronchial dilation having undergone a complete bilateral resection with an interval of 3 months. The average age of our patients varied between 17 and 59 years with an average of 39,9 years , we noted a predominance of bilateral bronchial dilatation for the age group between 40 and 59 years 60%. This affection affects both sexes with a clear predominance of women, 7 women 70% and 3 men 30%, or a sex ration of 0,42

The majority of our patients presented with dilation of the bronchi sequellar 60% namely :

Pulmonary tuberculosis microscopic positif : 3 cases

Pulmonary tuberculosis microscopic negatif: 1 case

1st degree tuberculosis contagion : 2 cases

In addition, there are 2 cases of kartegener syndrome and one case of Marfan disease. All the patients were symptomatic, the functional signs found were dominated by bronchorrhea 70% hemoptysis 50%. All our patients benefited from a radiological assessment ,standard X-ray and chest CT , on the scanographic plan we noted the predominance of cylindrical bronchiectasis which was present in 6 patients or 60% (Table 1 & Figure 1).

Type of Lesions	Number	Percentage
Cystic lesions	2	20%
Cylindrical lesions	6	60%
Varicose moniliforms	2	20%

Table 1: Distribution of Bilateral Bronchiectasis by type of Lesion

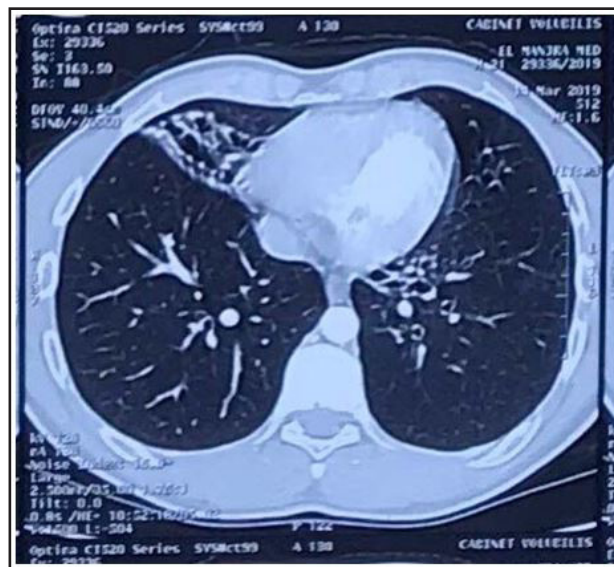


Figure 1: CT scan of a patient with grouped moniliform bronchial dilatation of the right middle lobe with some of cylindrical dilatation of the lower left lobe

Chest CT scan of a patient with grouped moniliform bronchial dilatation of the right middle lobe with a cylindrical bronchial dilatation on the left lower lobe. The bronchoscopy was performed in 10 patients or 100% cases, it showed a bronchial inflammatory aspect of the 1st degrees, spirometry was performed in 10 patients, the percentage relating to the theoretical value of the maximum expiratory volume per second varied between 52% and 92% with an average of 64,16%. 24H proteinuria was achieved with all patients which was negative in all cases. All our patients had benefited from preoperative preparation based on clinical data (congestion , superinfection ,and anemia) using respiratory physiotherapy to get a patient known as dry initiating an incentive spirometry which will be of a great use during the postoperative period functional (obstructive ventilatory disorder) prescription of bronchodilators, nebulization sessions besides biological examinations (CRP, Hyperleukocytosis identification of pathogenic strains) treating any documented secondary infection.

All 10 cases were operated by the surgical team of the department of thoracic surgery, University Hospital Hassan II-Fes, Morocco. The approach was a conservative posterolateral thoracotomy of the dorsal muscle, Duration of surgery was 2 hours in both groups; the most used type of excision is lobectomy with a percentage of 90% followed by segmentectomy with a percentage of 40%and least one used is that of the bi-segmentectomy with a percentage of 20%, in all lobectomies ;thus , protection of the bronchial stump was performed by the pleural flap, and the total hospital stay (ICU/ WARD) in group A and group B was the same in the two group : 4 days (Tables 2 & 3).

Patient	Age	Sex	Type of surgical excision
1	52	F	Medium lobectomy
2	42	F	Medium lobectomy
3	53	F	Atypical lingual resection
4	59	H	Atypical resection between the Nelson and the basal pyramid
5	52	H	Left lower lobectomy and resection of the lingual

Table 2: Dype of surgical excision for group A

Patient	Age	Sex	Type of surgical excision	
			1 st intervention	Second intervention
1	39	F	Middle lobectomy and sub -ventro-paracardiac segmentation	lower left lobectomy
2	43	F	Lower left lobectomy and lingual segmentation sub-segmental resection of the middle lobe	sub-segmental resection of the middle lobe
3	23	F	Middle lobectomy by postero lateral thoracotomy lingulectomy ventro-paracardiac under segmentectomy	lingulectomy ventro-paracardiac under segmentectomy
4	19	F	Middle lobectomy and left pericardiac segmentation resection of the basal pyramid and lingula	resection of the basal pyramid and lingula
5	17	H	Lingual resection with decortication of a pyopneumothorax	right upper lobectomy with a sub- segmentectomy of a right pneumothorax on DDB lesions .

Table 3: Type of surgical excision for group B

The anathomopathological examination was carried out on all the pieces of excision, it was conclusive in all cases. It highlighted an aspect of bronchiectasis in 6 cases 60% including the association with an aspergilloma in 1 case .further more, no active tuberculous lesion was found.

The postoperative results were judged mainly on the clinical symptoms , namely :

- a. Disappearance or decrease in episodes of hemoptysis.
- b. Quantitative and qualitative decrease or disappearance of the bronchorrhea volume .
- c. Absence or reduction of the annual secondary infections number (less than 2 episodes per year) were distributed over a period of follow up between 18 months and 4 years as such :
 1. Asymptomatic: Complete disappearance of the initial symptomatology , noted in 6 patients.
 2. Improvement: In absence of hemoptysis with less than 2 infections per year and a daily sputum volume of less than 10 ml, observed in 4 cases.
 3. Poor: Persistence or worsening of the symptomatology revealed in no case ;besides , a spirometric control was performed in 10 patients (Table 4 & 5).

Group A patient	Complications	Clinical evolution	Preoperative VEMS	Postoperative VEMS
1	Simple	Asymptomatique	92 %	95 %
2	Simple	Improvement	65 %	63 %
3	Simple	Improvement	54 %	49 %
4	Simple	Improvement	78 %	75 %
5	Simple	Improvement	59 %	61 %

Table 4: Clinical and Functional Respiratory Evolution of the Group A

Group B patient	complications	Clinical evolution		Spirometry		
		After the 1 st Intervention	After the 2 nd intervention	Before the 1 st intervention	After the 1 st Intervention	After the 2 nd intervention
1	Simple	Improvement	Asymptomatic	54 %	57 %	73 %
2	Simple	Improvement	Asymptomatic	53 %	64 %	76 %
3	Simple	Improvement	Asymptomatic	52 %	54 %	52 %
4	Simple	Improvement	Asymptomatic	84 %	64 %	80 %
5	Simple	Improvement	Asymptomatic	Drained patient	75 %	

Table 5: Clinical and Functional Respiratory Evolution of the Group B

Discussion

The surgical part in the management of bilateral bronchial dilatation was communicated in 1936 by Lewis [6] followed by the rare publications up to 2017. Jie Das showed the value of the targeted surgery on the predominance of the disease "target lesion" [7-9]. In our current practice, the surgical management of bilateral bronchial dilatations went on 3 steps :

1. At first we were adepts of the unilateral resection of the predominant lesion based on the realization of a lobectomy whatever the assessment .
2. Then we practiced complete unilateral resection with the realization of unique but often multiple segmentectomy .
3. And finally we practice a complete bilateral resection with bronchiectatic residue equal to 0.

In case of bilateral resection. The gesture will be performed in 2 steps since resection in a single step exposed to an increased risk of respiratory complications which can take on dramatic scale if bilateral . The more affected side will always be operated first ,because it's difficult to predict whether the second side eventually be operated or not .Depending on the patient's condition and compliance also since sometimes the resection of the first side is sufficient to improve the symptomatology.

Yuncu [10], Kutlay [11], Prieto [12], and Fujimoto [13] also have concluded that the functional results after complete resection of the pulmonary territories affected was significantly better than those obtained with incomplete resection ($p < 0,05$) [14]. Our results are similar to those found in the literature. Thus complete resection of the pulmonary territories affected was also linked to our series ,hence this significantly has a good functional results. Jie Dain [6] when realized it as a type of excision a lobectomy of unilateral predominant lesion. Patient satisfaction after surgery was as follows :

- a. Excellent improvement in 62% patients
- b. Good improvement in 27% patients.
- c. Aggravation or persistence of symptoms at 10,8%

Conclusion

The surgical treatment of bronchiectasis remains an interesting alternative whose morbidity and mortality are weak and which have to be properly proposed to patients in case of complications of the bronchiectasis or a deterioration in the quality of life that persists despite of good medical treatment. In these bilateral bronchiectasis ,the surgical intervention will be ideally be a gesture of a complete bilateral resection in 2 steps of the lesions of bronchiectasis.since it results in lower morbidity and better long term benefit than complete resection . Our results must be confirmed by further prospective randomized studies.

References

1. Ndiaye A, Salmane Ba P, Diatta S, Thiam K, Dieng PA, et al. (2015) Surgical aspects of dilation of the bronchi: about 72 patients. *Chir Thor Cardio-Vasc* 19: 219-22. (Aspects chirurgicaux de la dilatation des bronches : à propos de 72 patients).
2. Rabiou S, Issoufou I, Ammor FZ, Harmouchi H, Belliraj L, et al. (2017) Results of bronchiectasis surgery: About 64 cases. *Rev Pneumol Clin* 73: 199-205. (Résultats chirurgicaux à propos de 64 patients opérés pour dilatations des bronches).
3. Brinchault G, Morel V, Meunier C, Belleguic C, Delaval P (2004) Dilations of the bronchi Bronchiectasis. *EMC Med* 1: 131-40 (Dilatations des bronches – bronchiectasie).
4. De Dominicis F, Andrejak C, Monconduit J, Merlusca G, Berna P (2012) Bronchial dilation surgery. *Rev pneumol clin* 68: 91-100. (Chirurgie de la dilatation des bronches).
5. Elhamdani Hajar (2015) Surgery of localized bronchial dilations thoracic surgery faculty of medicine and Marrakech. (Chirurgie des dilatations des bronches localisées chirurgie thoracique faculté de medecine et de Marrakech).
6. Lewis I (1936) Bilateral Lobectomy for Bronchiectasis. *Brit J Surg* 24: 362-7.
7. Dai J, Zhu X, Bian D, Fei K, Jiang G, et al. (2017) Surgery for predominant lesion in non localized bronchiectasis. *J Thorac Cardiovasc Surg* 153: 979-85.
8. Dogan R, Alp M, Kaya S, Ayrancıoğlu K, Taştepe I, et al. (1989) Surgical treatment of bronchiectasis: a collective review of 487 cases. *Thorac Cardiovasc Surg* 37: 183-6.
9. Bagheri R, Haghi SZ, Fattahi Masoum SH, Bahadorzadeh L, et al. (2010) Surgical management of bronchiectasis: analysis of 277 patients. *Thorac Cardiovasc Surg* 58 : 291-94.
10. Yuncu G, Ceylan KC, Sevin S, Ucvet A, Kaya SO (2006) Functional results of surgical treatment of bronchiectasis in a developing country. *Arch Bronconeumol* 42: 183-4.
11. Kutlay H, Cangir AK, Enon S, Sahin E, Akal M, et al. (2002) Surgical treatment in bronchiectasis: analysis of 166 patients. *Eur J Cardiothorac Surg* 21: 634-37.
12. Mohamed Jaber C (2017) The Pathways in Thoracic Surgery Year. (LES VOIES D'ABORD EN CHIRURGIE
13. Fujimoto T, Hillejan L, Stamatis G (2001) Current strategy for surgical management of bronchiectasis. *Ann Thorac Surg* 72: 1711-5.
14. Jougeon J, Delcambre F, Velly JF (2004) Surgical approaches to the thorax. *EMC pp.* 42-210 (Voies d'abord chirurgicales du thorax).