

## Poultry Coccidiosis and its Prevention, Control

Abdisa T\*, Hasen R, Tagesu T, Regea G and Tadese G

*Jimma University, School of Veterinary Medicine, Jimma, Oromia, Ethiopia*

**\*Corresponding author:** Abdisa T, Jimma University, School of Veterinary Medicine, Jimma, Oromia, Ethiopia, Phone: +251933681407, E-mail: abdisatagesu@gmail.com

**Citation:** Abdisa T, Hasen R, Tagesu T, Regea G, Tadese G (2019) Poultry Coccidiosis and its Prevention, Control J Vet Ani Res 2: 101

**Article history:** Received: 12 February 2019, Accepted: 11 March 2019, Published: 13 March 2019

### Abstract

Coccidiosis is the commonest and most important disease of poultry resulting in great economic losses worldwide. Therefore, the aim of this paper is to review on poultry coccidiosis. It is caused by the intracellular protozoa parasite of *Eimeria* species in the genus *Eimeria*. About nine species of *Eimeria* have been recognized in domesticated chickens, of which *Eimeria brunette*, *Eimeria maxima*, *Eimeria necatrix*, *Eimeria tenella* are the most pathogenic; *Eimeria acervulina*, *Eimeria mivati* are the less pathogenic and *Eimeria praecox* and *Eimeria hagani* are the lesser pathogenic. The disease is endemic in most of the tropical and subtropical regions where ecological and management conditions favour an all-year round development and propagation of the causal agent. Clinical signs are associated with tissue destruction from the release of the merozoites and mature oocysts from the mucosal surface during the last generations of merogony and throughout gametogony. Diagnosis of coccidiosis in chicken is best accomplished by postmortem examination of representative number of birds. Prevention of avian coccidiosis is based on a combination of good management and the use of anticoccidial compounds in the feed or water. Coccidiosis is recognized as the parasitic disease that has the greatest economic impact on poultry production. It is also endemic in Ethiopia, causing great economic losses particularly in young birds, in all production systems. Thus, proper treatment and management should be carried out to decrease the impact of coccidiosis on the economy of developing country.

**Keywords:** Coccidiosis; Chickens; Diagnosis; *Eimeria*; Prevention

### Introduction

Parasitic diseases have remained the major problem limiting the expansion and profitability of the developing agricultural countries, where skilled husbandry in-puts have not matched the rate of expansion and intensification of poultry holdings [1, 2]. Poultry coccidiosis is one of the most common and economically most important diseases of poultry worldwide [3].

Coccidiosis is caused by the intracellular protozoa parasite of *Eimeria* species in the genus *Eimeria* family *Eimeridae* order *Eucoccidiorida* and phylum *Apicomplexa* [4]. *Eimeria* colonize and infect the intestinal tract of different animals and birds (Haug et al., 2008) and infection with this parasite normally occurs through ingestion of feed or water contaminated with sporulated oocysts [5, 6]. About nine species of *Eimeria* have been recognized in domesticated chickens, of which *Eimeria brunette*, *Eimeria maxima*, *Eimeria necatrix*, *Eimeria tenella* are the most pathogenic; *Eimeria acervulina*, *Eimeria mitis*, *Eimeria mivati* are the less pathogenic and *Eimeria praecox* and *Eimeria hagani* are the lesser pathogenic [7].

Infections caused by coccidian parasites have had a major economic impact on the commercial broiler industry in the past several decades. It is endemic in most of the tropical and subtropical regions where ecological and management conditions favor an all year-round development and propagation of the causal agent [8]. Poultry coccidiosis is one of these diseases causing significant poultry losses in Ethiopia [9]. Coccidiosis resulting from the pathogenic *Eimeria* species is usually characterized by dysentery, enteritis, diarrhea, which may be bloody with certain *Eimeria* species, emaciation, lower feed conversion rate, delayed sexual maturity, drooping wings, poor growth and low production with attendant high mortality and morbidity rates [10].

The most common and pathogenic species that affects the poultry industry globally is the *E. tenella* with 100% morbidity and a high mortality due to extensive damage of the digestive tracts of chickens [11,12]. Mortality rates are usually high in young chicks, because most of the *Eimeria* species affects birds between the age of 3 and 18 weeks [13]. The occurrence of clinical coccidiosis is directly related to the number of oocysts ingested by poultry at one time, the pathogenicity of the *Eimeria* species, the age of the infected chicken and the management system [6].

The most frequent symptoms is at the beginning yellow diarrhea then become depressed, have ruffled feathers, the wings droop and

tend to huddle together [14]. High incidence of coccidiosis is usually observed in poultry managed under intensive management system like deep litter due to increased likelihood of high oocysts accumulation in the litters [15]. Furthermore, higher stocking densities have been linked with increased incidence of coccidiosis due to a higher rate of infection and transmission of the coccidian oocysts in dense flocks from one poultry house to another [16].

For the control of coccidiosis in chickens and turkeys, a number of preventive medications have been approved for use worldwide, but reduced sensitivity and resistance are increasingly important as no new anticoccidial compounds are known to be under development [17]. The traditional control of coccidiosis mainly relies on chemoprophylaxis, which appeared to be effective in the last decades. However, the increased occurrence of resistance against routine anti-coccidial drugs has left the poultry industry with a renewed challenge for coccidiosis prevention and control and propelled the search for alternative strategies among which vaccination is of major importance [18]. Therefore, the objective of this paper is to review on poultry coccidiosis.

## Literature Review

### Poultry Coccidiosis

Avian coccidiosis is an enteric parasitic disease caused by multiple species of the protozoan parasite of the genus *Eimeria*. Coccidiosis is the commonest and most important disease of poultry resulting in great economic losses worldwide [19].

### Etiology

Among the infectious diseases of poultry, coccidiosis is the major parasitic disease. Poultry coccidiosis is an economically important disease in chicken caused by the intracellular protozoa parasite of *Eimeria* species in the genus *Eimeria* family *Eimeridae* order *Eucoccidiorida* and phylum [4]. Seven species of *Eimeria* (*E. acervulina*, *E. brunetti*, *E. maxima*, *E. mitis*, *E. necatrix*, *E. praecox* and *E. tenella*) are recognized as infecting chickens as it detailed in Table 1. Although coccidiosis is a disease known for many years, it is still considered as the most economical important parasitic condition affecting poultry production worldwide.

<i>E.tenella</i>	Caecum
<i>E.acervulina</i>	Duodenal loop
<i>E.necatrix</i>	Mid gut
<i>E.maxima</i>	Mid gut
<i>E.hagani</i>	Anterior gut
<i>E.mivati</i>	Duodenal
<i>E.praecox</i>	Anterior gut
<i>E.mitis</i>	Anterior gut
<i>E. brunette</i>	Lower intestine

Source: (Foreyt, 2001) [20]

**Table 1:** *Eimeria* Species with their Predilection Site in Intestine of Poultry

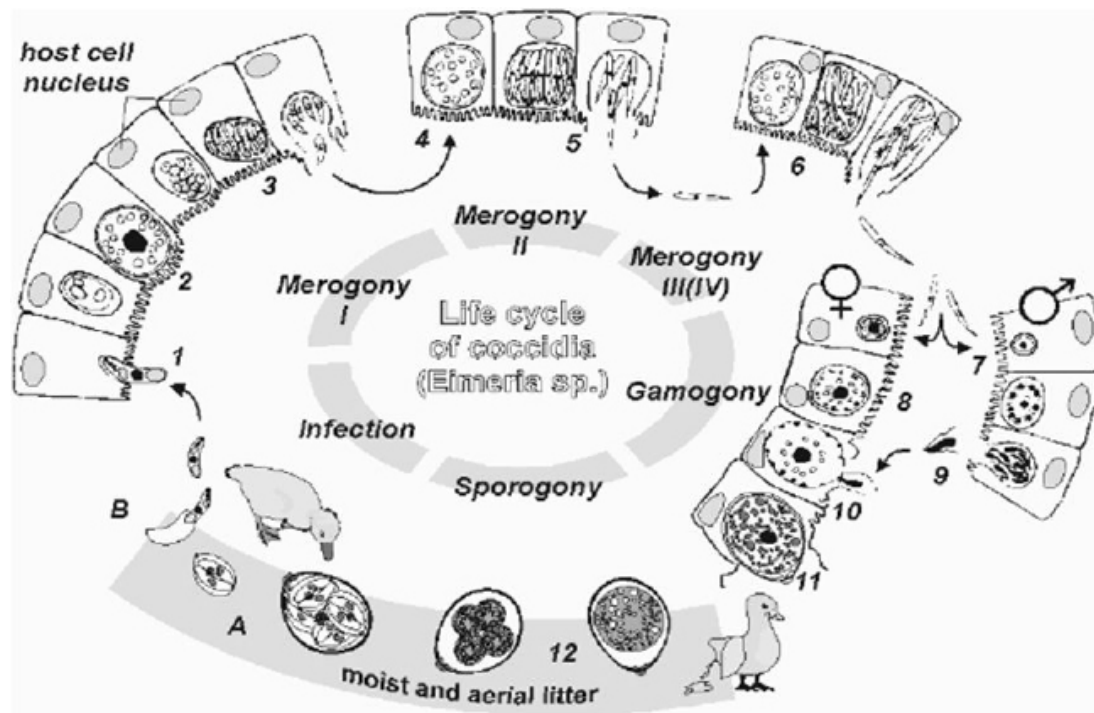
### Morphology

Majority of *Eimeria* oocysts have ovoid shape. Other characteristics that is useful in species identification includes: zone of intestine parasitized, nature of macroscopic lesions, minimum sporulation time, minimum prepatent period, schizonts size and area in which it develops, location of the parasite within the epithelial cells and cross-immunity trails [21].

### Lifecycle

The life cycle of all *Eimeria* species involves two or more generation of an asexual development known as shizogony, followed by a sexual phase formed by gametogony which results in the formation of oocyst [22]. The infective stage, sporulated oocyst, is ingested and the action of mechanical and chemical factors in the gut (bile salt and trypsin) leads to the release of sporocysts and then sporozoites in the duodenal lumen and this stage is described in Figure 1.

The sporozoites invade the mucosa sometimes passing down the whole length of the alimentary tract before doing so. Then follow phases of intracellular growth and asexual multiplication with periodic release of merozoites entering in to the sexual phase of the life cycle known as gametogenesis [23]. These merozoites invade cells and develop in to either macro- gametes or micro- gametes. The former gives rise to a single macrogamete whereas the male gametocyte matures and ruptures, releasing seven large number of minute biflagellate micro-gametes. The micro-gametocyte grows to form a micro-gamete. A thickened wall forms around the macro-gamete, forming a zygote when the macro gamete is fertilized by microgamete. This stage is the young or immature oocyst [24].



(Source: Fanatico, 2006) [25]

Figure 1: Life cycle of *Coccidia* in poultry

## Epidemiology

The disease is endemic in most of the tropical and subtropical regions where ecological and management conditions favour an all-year round development and propagation of the causal agent [8]. The occurrence of different *Eimeria* species combinations and the intensity of infection vary considerably, both locally and globally [5]. High incidence of coccidiosis is usually observed in poultry managed under intensive management system like deep litter due to increased likelihood of high oocysts accumulation in the litters [13]. In Ethiopia, poultry coccidiosis caused by (*E. acervulina*, *E. necatrix*, *E. maxima* and *E. tenella*), is endemic in all parts of the country and affects mainly young growing birds [9].

**Agent related risk factors of Coccidial infection in poultry:** The occurrence of poultry coccidiosis is dependent on both the species of *Eimeria* and the size of the infecting dose of oocysts. Due to the short prepatent period of the parasite and its high biotic potential, the number of oocysts in the litter rises rapidly [26]. Poultry *coccidia* have high capacity to reproduce within the host; this leads to high level of the parasite within the susceptible host and subsequently high level of contamination of the environment [27].

**Host related risk factors:** Coccidiosis is usually a disease of young birds, but birds can be infected at any time, if never exposed before. *Coccidia* populations take time to build dangerous levels, therefore, outbreaks usually occur when birds are between 3 and 8 weeks of age [25]. High animal density cramped on a small space, age of the bird at the time of the first infection and number of passages of the infection as well as on ability of the bird to develop proper specific immune response [28].

**Environmental and management related risk factors:** Management of poultry houses plays a momentous function in the spread of coccidiosis because coccidial oocysts are omnipresent and are easily spread in the poultry house environment. Further, owing to their high reproduction potential, it is very complex to keep chickens *coccidia* free, especially under current intensive rearing [29]. Prevalence varied by management and did not vary by flock size while bad management, such as wet litter that encourages oocyst sporulation, contaminated drinkers and feeders, bad ventilation, and high stocking density, can worsen the clinical signs [12, 30].

## Pathogenesis

Infection by *coccidia* in sufficient number to produce clinical manifestations of disease is called coccidiosis [31]. Though nine species of *Eimeria* have been identified as causative agents of poultry coccidiosis, only seven of them have been reported to be pathogenic [32]. *Eimeria tenella* (*E. tenella*) and *Eimeria necatrix* (*E. necatrix*) are the most pathogenic species. *Eimeria acervulina* (*E. acervulina*), *Eimeria maxima* (*E. maxima*) and *Eimeria mivati* (*E. mivati*) are common and slightly too moderately pathogenic while *Eimeria brunetti* (*E. brunetti*) is uncommon but pathogenic when it does occur. *Eimeria praecox* (*E. praecox*) and *Eimeria hagani* (*E. hagani*) are relatively non-pathogenic species [33].

Oocysts passed in the feces require suitable environmental conditions to sporulate. Moist, temperate, or cool conditions favor sporulation, whereas high temperatures and dryness impede it [34]. Coccidiosis outbreaks are commonly classified according to the areas of the digestive tract for which the particular species of *coccidia* seem to have a special affinity. The protozoan parasite

of the genus *Eimeria* multiplies in the intestinal tract and causes tissue damage, resulting in the interruption of feeding, digestive processes, nutrient absorption, dehydration, blood loss, loss of skin pigmentation and increased susceptibility to other disease pathogens [35].

### Clinical Sign

Avian coccidiosis, caused by parasites of the genus *Eimeria*, produces anorexia and reduced weight gain and feed conversion in infected chicks [36]. *Eimeria tenella* causes moderate to severe cecal lesions, sometimes death. The birds become depressed, have ruffled feathers, the wings droop, have diarrhea and tend to huddle. Food and water consumption usually decreases and may become emaciated and dehydrated. Laying hens will experience a reduction in rate of egg production. Cecal coccidiosis may produce bloody droppings and anemia [37].

Clinical signs are associated with tissue destruction from the release of the merozoites and mature oocysts from the mucosal surface during the last generations of merogony and throughout gametogony. In severe infections, much of the mucosal epithelium is sloughed off and nutrient absorption is compromised [38].

### Diagnosis

Diagnosis of coccidiosis in chicken is best accomplished by postmortem examination of representative number of birds. Diagnosis by fecal examination may lead to quite erroneous results [33]. In some instances the major pathology is produced before oocysts are shed in the feces (*E. tenella*) and, conversely, the presence of large number of oocysts may not necessarily indicate a serious pathogenic condition. Thus, with *E. acervulina*, which has a high biotic potential, comparatively larger numbers of oocysts are shed than, for example, with *E. necatrix*. Furthermore, the accurate identification of the oocysts of various poultry *coccidia* is not easy [34].

In recent years, various biochemical and molecular methods have also been [18]. As indicated, next to the fact *Eimeria* are very effective parasites, one of the main reasons coccidiosis is still a major problem, is the difficult diagnosis. The classical parasitological methods of diagnosis are labor intensive and therefore costly. Oocyst per gram (OPG) counts in faeces or litters have a poor relation with the impact of the parasite on the performance of a flock. Identification of different species based on morphology of oocysts is very challenging and requires expertise [17].

Diagnosis of clinical disease caused by *E. tenella* is quite easy and action (therapy on the short term, change of preventive means on the long term) can be swift. These facts make its impact on the productivity of the broiler industry is relatively limited compared to the other species, although many broiler farmers associate coccidiosis only with caecal coccidiosis. This is a good example of perception not being in accordance with the facts. *E. acervulina* and *E. maxima*, both much more prevalent, are less perceived to be related with clinical coccidiosis in the field. *E. acervulina* is causing white lesions in duodenum and in heavier infections also more caudal, interfering even with the ability for *E. maxima* to develop [39].

### Necropsy Findings

The type and locations of lesions in the gut indicates the species of *Eimeria*. *Eimeria acervulina* affects the upper parts of the small intestines, you may see small red spots and white bands on it; *E. maxima* affect the entire small intestine; the intestine looks watery and in later stages have blood and mucus. The intestine may look thickened and ballooned with red pinpoint lesions. *Eimeria tenella* affects the blind sacks of the gut. The intestine may be filled with blood and pus and turn in to a solid core [25]. Histopathologically, the wall of the gut is thickened indicating retention of fluid (edema). There may be blood in the lumen of the gut indicating blood loss (hemorrhage), or merely retention of an excessive amount of blood in the tissue (hyperemia) there is also infiltration with various body reactions and the development of immune response [40].

### Treatment, Control and Prevention

The effective use of anticoccidial feed additives over the past 50 years has played a major role in the growth of the poultry industry and has allowed the increased availability of high quality, affordable poultry products to the consumer. There are basically two means of prevention of coccidiosis: chemoprophylaxis and vaccination. Chemoprophylaxis using so-called anticoccidial products (ACP) or anticoccidials in the ration is by far the most popular [41].

Coccidiosis is by far more easily prevented than treated; Drugs have been very important in controlling coccidiosis but the emergency of coccidial drug resistance has affected the use of fullness of the drugs. The possibility that drugs may not always be relied up on to control coccidiosis has led to an interest in other means of control [42]. Apart from the use of drugs, control is now based on hygiene, vaccine and genetics. But genetics is a theoretical strategy not in practical use [26].

Prevention of avian coccidiosis is based on a combination of good management and the use of anticoccidial compounds in the feed or water. Litter should always be kept dry and special attention should be given to litter near water fonts or feeding troughs [4, 43]. The prophylactic drugs used for prevention of coccidiosis are coccidiosis stats. An effective coccidiosis stat should inhibit the schizogonic stage and allow immunity to develop. Prophylactic use is performed because most of the damage occurs before signs

become apparent and because drugs cannot completely stop an outbreak [14].

### Economic Importance of Poultry Coccidiosis

Coccidiosis is one of diseases of poultry that play inhibitory role in the growth of this industry. It is a disease complex of poultry caused by different species of parasite of *Eimeria*. It inflicts the birds in both clinical and sub-clinical forms. The clinical form of the disease manifests through prominent signs of mortality, morbidity, diarrhoea or bloody faeces and sub-clinical coccidiosis manifests mainly by poor weight gain and reduced efficiency of feed conversion and gives rise to highest proportion of the total economic losses [44].

### Current Status of Poultry Coccidiosis in Ethiopia

The prevalence of poultry coccidiosis has been reported in different part of Ethiopia in different years (Prevalence of Coccidiosis was reported by researcher; Gebremeskel and Tesfa, 2016; Oljira, 2012; Alemayehu, *et al.* 2012; Feyisa and Chalchisa, 2017) as listed as, 20.57%, 28.2%, 25.5% and 39.6% respectively. The variation of this all prevalence of coccidiosis may be due to epidemiology of study time, breed and management system differences and possibility of drug resistance [45-48].

### Conclusion and Recommendation

Coccidiosis is an important enteric parasitic disease of poultry associated with significant economic losses to poultry farmers worldwide. It has been indicated that there are several species of *Eimeria* affect chickens with varying pathogenicity. The occurrence of coccidiosis dependent on agent, host and management as well as environment associated risk factors. The presence of lesions and part of intestine affected in combination with histo- pathology could help in better diagnosis of coccidiosis. Anticoccidials and good management are important for control and prevention of coccidiosis in domestic chickens.

Therefore, based on above conclusion the following recommendations are forwarded:

- Proper diagnostic methods and biosecurity measures should be performed to prevent and control the disease in the chickens.
- Proper prophylactics treatment and management should be carried out to decrease the impact of coccidiosis on the economy of developing country.
- To control this economically important parasitic disease of poultry, further studies need to be undertaken to come up with sustainable and cost-effective prevention and control methods.

### Reference

1. Mohammed BR, Sunday OS (2015) An overview of the prevalence of avian coccidiosis in poultry production and its economic importance in Nigeria. *Vet Res Int* 3: 35-45.
2. Adene DF, Oluleye OB (2004) The biology diagnosis, treatment and control. *Poultry Health and Production Principles and Practices*. Ibadan, Nigeria: Stirling-Horden Publishers 129: 64.
3. Olanrewaju CA, Agbor RY (2014) Prevalence of coccidiosis among poultry birds slaughtered at Gwagwalada main market, Abuja, FCT, Nigeria. *Int J Eng Sci* 3: 41-5.
4. Taylor MA, Coop, Wall RL (2007) *Veterinary Parasitology* (3rd Edn). Oxford, UK, Blackwell Publishing 475-83.
5. Haug A, Gjevne AG, Thebo P, Mattsson JG, Kaldhusdal M (2008) Coccidial infections in commercial broilers: epidemiological aspects and comparison of *Eimeria* species identification by morphometric and polymerase chain reaction techniques. *Avian pathol* 37: 161-70.
6. Allen PC, Fetterer RH (2002) Recent advances in biology and immunobiology of *Eimeria* species and in diagnosis and control of infection with these coccidian parasites of poultry. *Clin microbiol Rev* 15: 58-65.
7. Jadhav BN, Nikam SV, Bhamre SN, Jaid EL (2011) Study of *Eimeria necatrix* in broiler chicken from Aurangabad District of Maharashtra state India. *Int Multi Res J* 1.
8. Obasi OL, Ifut OJ, Offiong EA (2006) An outbreak of caecal coccidiosis in a broiler flock post Newcastle disease vaccination. *J Anim Vet Adv* 5: 1239-41.
9. Safari M, Kinung H, Getachew T, Hafez W, Moges K, et al. (2004) Assessment of Economic impact caused by poultry coccidiosis in small and large scale poultry farm in Debrezeit, Ethiopia. *Int J Poult Sci* 3: 715-25.
10. Awais MM, Akhtar M, Iqbal Z, Muhammad F, Anwar MI (2012) Seasonal prevalence of coccidiosis in industrial broiler chickens in Faisalabad, Punjab, Pakistan. *Trop Anim Health Prod* 44: 323-8.
11. Ayaz MM, Akhtar M, Hayat CS, Hafeez MA, Haq A (2003) Prevalence of coccidiosis in broiler chickens in Faisalabad, Pakistan. *Pak Vet J* 23: 51-2.
12. Hadipour MM, Olyaie A, Naderi M, Azad F, Nekouie O (2011) Prevalence of *Eimeria* species in scavenging native chickens of Shiraz, Iran. *Afr J Microbiol Res* 5: 3296-9.
13. Dakpogan HB, Salifou S (2013) Coccidiosis prevalence and intensity in litter based high stocking density layer rearing system of Benin. *J Anim Plant Sci* 17: 2522-6.
14. Kahn CM (2005) *The Merck Veterinary Manual* (9th Edn). White house station, NJ, USA, 2201-6.
15. Nnadi PA, George SO (2010) A cross-sectional survey on parasites of chickens in selected villages in the subhumid zones of South-Eastern Nigeria. *J Parasitol Res*.

16. Lunden A, Thebo P, Gunnarsson S, Hooshmand-Rad P, Tauson R., et al. (2000) Eimeria infections in litter-based, high stocking density systems for loose-housed laying hens in Sweden. *Br Poult Sci* 41: 440-7.
17. De Gussem M (2007) Coccidiosis in poultry: review on diagnosis, control, prevention and interaction with overall gut health. In *Proc 16th Eur Symp Poult Nutr* 253-61.
18. Morris GM, Gasser RB (2006) Biotechnological advances in the diagnosis of avian coccidiosis and the analysis of genetic variation in Eimeria. *Biotechnol Adv* 24: 590-603.
19. Latif AA, Fazal S, Manzoor F, Maqbool A, Asghar S, et al. (2016) A Comparative Study on Prevalence of Coccidian Parasites in Broiler Chicken (*Gallus gallus domesticus*), Japanese Quail (*Coturnix coturnix japonica*) and Wild Pigeon (*Columba livia*). *Pak J Zool* 48: 295-7.
20. Foreyt WJ (2001) *Veterinary parasitology reference manual* (5th Edn). Iowa state Univ Press, Ames, USA.
21. Reid WM (1978) *Coccidiosis. Diseases of Poultry* (7th Edn). Iowa State University Press, Ames, Iowa, USA, 784-805.
22. Kaufmann J (1999) *Parasitic Infections of Domestic Animals*. Germany, Birkhauser, 341-2.
23. Jones CT, Hunt DR, King WN (1996) *Veterinary Pathology* (6th Edn) USA Lippincott Williams Wilkins 552.
24. Conway DP, McKenzie ME (2007) Poultry coccidiosis: diagnostic and testing procedures. *J Vet Sci* 5: 22-35.
25. Fanatico A (2006) Parasite management for natural and organic poultry Coccidiosis. *ATTRA Natl Sustainable Agric Inf Serv* 1-12.
26. Jordan F, Pattison M, Alexander D, Faragher T (2002) Parasitic diseases. In: *Poultry Disease* (5th Edn) Hong Kong, WB Saunders, 405-20.
27. Urquhart GM, Armour J, Duncan JL, Dunn AM, Jennings FW (1987) *Vet Parasitol*. Longman Group UK Ltd, UK, 345.
28. Hofstad MS (1984) *Diseases of Poultry* (8th Edn). Iowa State Univ Press, Ames, USA, 692-717.
29. Adhikari A, Gupta R, Pant GR (2008) Prevalence and identification of coccidian parasite (*Eimeria* spp) in layer chicken of Ratnanagar Municipality, Chitwan district, Nepal. *J Nat Hist Mus* 23: 45-50.
30. Al-Quraisy S, Abdel-Baki AS, Dkhil MA (2009) Eimeria tenella infection among broiler chicks Gallus domesticus in Riyadh city, Saudi Arabia. *J King Saud Univ Sci* 21: 191-3.
31. Charlton BR (2006) Coccidiosis. In: *Avian disease manual* (5th Edn) India: International book distributing company in association with American association of avian pathologist, USA, 153-6.
32. Kahn CM (2008) *The Merck Veterinary Manual* (9th Edn). White house station, NJ, USA, Merck and CO, INC 2201-6.
33. Soulsby EJJ (1982) *Helminths, Arthropods and Protozoans of Domesticated Animals* (7th Edn) London: Bailliere Tindall, 167-9.
34. Radostits OM, Gay C, Hinchcliff KW, Constable PD (2007) *A textbook of the diseases of cattle, sheep, goats, pigs and horses*. Veterinary Medicine (10th Edn). Bailliere, Tindall, London, UK, 76-1580.
35. McDougald LR, Fitz-Coy SH (2008) Protozoal infection, In *YM Saif* (12th Edn). *Dis Poult*.
36. Safari M (2001) Studies on prevalence and economic impact of poultry coccidiosis in different production systems in Debre Zeit and Addis Ababa, Ethiopia. Doctoral dissertation, MSc thesis, FVM, AAU, Ethiopia.
37. Whitmarsh Sh (1997) *Protozoan Poultry Diseases*. *Poult Sci Home Page*, College Agric Sci Mississippi State Univ.
38. Yun CH, Lillehoj HS, Lillehoj EP (2000) Intestinal immune responses to coccidiosis. *Dev Comp Immunol* 24: 303-24.
39. Mathis GF, Broussard C (2006) Increased level of Eimeria sensitivity to diclazuril after using a live coccidial vaccine. *Avian Dis* 50: 321-4.
40. Marquardt CW, Demaree SR, Grieve BR (2000) *Parasitology and vector biology* (2nd Edn). San Diego, London, Boston, New York, Tokyo, Toronto, 152.
41. Chapman HD (2005) Perspectives for the control of coccidiosis in poultry by chemotherapy and vaccination. In *Proc IXth Int Coccidiosis Conf*, Foz de Iguassu, Parana, Brazil. *Apinco Found Poult Sci Technol Campinas, São Paulo, Brazil*, 99-103.
42. Vegad JL (2004) Poultry coccidiosis. In: *Poultry Diseases, a guide for farmers and poultry professionals*. Int Book Distributing Company 186-197.
43. Urquhart MG, Armour J, Duncan LJ, Dunn, Jennings WF (1996) *Veterinary Parasitology* (2nd Edn) Scotland: Univ Glasgow 228-31.
44. Williams RB (1999) A compartmentalised model for the estimation of the cost of coccidiosis to the world's chicken production industry. *Int J Parasitol* 29: 1209-29.
45. Gebremeskel AK, Tesfaye E (2016) Prevalence of poultry coccidiosis in and around Yabello, southern Ethiopia. *J Vet Med Anim Health* 8: 244-7.
46. Oljira D, Melaku A, Bogale B (2012) Prevalence and risk factors of coccidiosis in poultry farms in and around Ambo Town, Western Ethiopia. *Am-Eurasian J Sci Res* 7: 146-9.
47. Alemayehu T, Tekeselassie A, Kassa SA (2012) Prevalence study of poultry coccidiosis in small and large-scale farms in Addis Ababa, Ethiopia. *J Crop Sci* 1: 26-31.
48. Fayissa BD, Chalchisa T (2016) Poultry coccidiosis: Prevalence and associated risk factors in extensive and intensive farming systems in Jimma Town, Jimma, Ethiopia. *J Vet Med Anim Health* 8: 223-7.
49. Fessesse-work (1990) Poultry Coccidiosis and Effect of Management System: An Assessment Trial in Debre Zeit and its Surroundings. Faculty Vet Med Addis Ababa Univ, Debre Zeit, DVM Thesis.
50. Zahraddeen D, Butswat ISR, Sanusi M, Adamu SA (2010) Characterization of poultry farming in Nigeria: A case study of Taraba state. *J Anim Vet Res* 2: 1-8.