

Peculiarities of Fissural Hydatid Cysts of Lung: About 39 Cases

M Lakranbi¹, H Harmouchi^{1*}, FZ Ammor¹, L Belliraj¹, R Sani¹, Y Ouadnoui² and M Smahi²

¹Department of Thoracic Surgery, University Hospital of Fes, Morocco

²School of Medicine and Pharmacy, University of Sidi Mohammed Ben Abdellah Fes, Morocco

***Corresponding author:** H Harmouchi, Department of Thoracic Surgery, University Hospital of Fes, Morocco, Tel: 664153156, E-mail: harmouchi.hicham@gmail.com

Citation: M Lakranbi, H Harmouchi, FZ Ammor, L Belliraj, R Sani, et al. (2020) Peculiarities of Fissural Hydatid Cysts of Lung: About 39 Cases. J Surg Sci Oper Care 2: 103

Article history: Received: 09 April 2020, Accepted: 27 May 2020, Published: 28 May 2020

Abstract

Introduction: The objective from this work is to determinate the epidemiological, diagnostic, therapeutic, evolution and prophylactic Peculiarities of scissural hydatid cyst of lung.

Patients and Methods: This study was conducted over a period of 8 years (2010 to 2017), with a history of pulmonary hydatid cyst confirmed to intraoperative exploration.

Results: There were 21 men and 18 women (mean age 33.7 years). The cough presented in 35 cases (90%), and hydatid vomit in 14 cases (33%). The procedure is based on the general practice of thoracic surgery, and is conservative, with a conservative approach to thoracotomy in all our patients. scissuralhydatid cyst were treated with pericytectomy in the majority of cases (77%). Postoperative follow-up was simple in 89.7% of cases.

Conclusion: SHC is rarely reported but remains the most common location of extrapulmonary chest hydatid cysts. Awaiting an effective control strategy, surgery remains the best therapeutic choice.

Keywords: Hydatid cyst; Fissure; Surgery; Prevention

Introduction

The hydatid pulmonary cyst is still a major public health problem in Morocco [1]. The pulmonary localization of hydatidosis comes second in adults after the liver. The site of hydatid pulmonary cyst between the different fissures is not uncommon in a country endemic for hydatidosis, but less frequent than the intra-pulmonary site. To our knowledge, this article is the first manuscript to discuss this particular localization of pulmonary hydatid cyst. The goal of this study is to report our experience in the different epidemiological, diagnostic, therapeutic, evolutionary and prophylactic approaches of this pathology.

Material and Methods

This is a retrospective study for descriptive purposes relating to patients operated for fissural hydatid cyst, treated within the thoracic surgery department of the Hassan II teaching hospital in Fez over a period of 7 years from January 1, 2010 to December 31, 2017. All the epidemiological, clinical, radiological and therapeutics aspects were studied.

Results

39 patients were operated for fissural hydatid cyst in this period

Epidemiological Results

The age of the patients varies between 9 and 80 years with an average of 33.7. Out of 39 patients, we noted a male predominance with 21 men (54%) and 18 women (46%), with a sex ratio of 1.16 M / F. The rural origin of the patients was clearly predominant with 30 cases (77%). A notion of contact with dogs was found in 34 patients (83%).

Clinical and Radiologic Aspects

A history of hydatid cyst management had been found in 5 patients, 4 had undergone surgical treatment (all had taken antelmintic treatment postoperatively for 6 months). Cough was the main symptom, found in 35 patients (90%), with chest pain in 25 patients

(64%), and hemoptysis in 21 patients (54%). Hydatid sputum was present in 14 patients (33%). The clinical examination found fluid effusion syndrome in 25 patients (64%).

The radiological assessment (chest radiography of face and chest CT) objectified a liquid mass in 24 patients (61%), an aspect of a floating membrane in 10 patients (26%), an aspect of bell in 4 patients (10%), and air liquid level appearance in a single patient (3%) (Figures 1 & 2). The abdominal ultrasound was done in all patients returning normal in 32 patients (82%), and objectifying a hydatid liver cyst in 6 patients (15%), and in a single patient (3%) a hydatid liver cyst associated with a cyst splenic hydatid. Bronchial fibroscopy performed in 25 patients (64%) objectified hydatid membranes only in 4 patients (10%). Hydatid serology was done in 23 patients (59%) returning positive in 11 cases (28%).

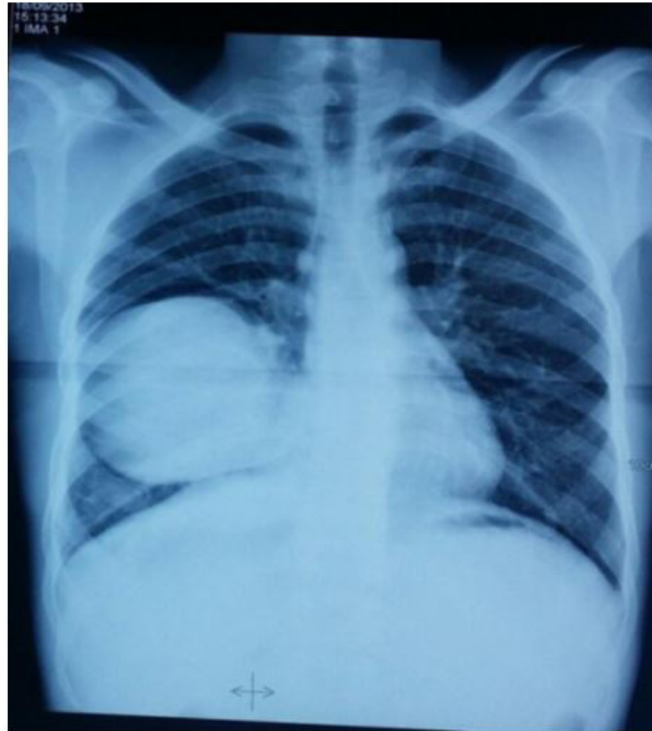


Figure 1: Chest x-ray showing fissural location of an unbroken right pulmonary hydatid cyst

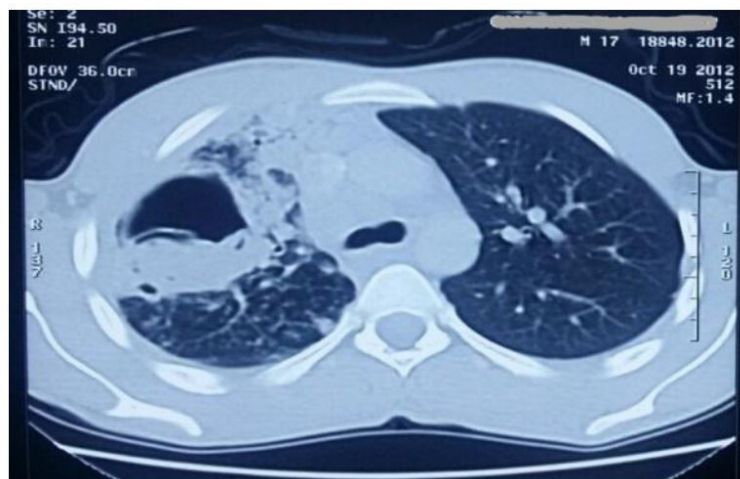


Figure 2: Chest scan in a parenchymal window showing a right fissural hydatid cyst ruptured with hydatid membranes

Therapeutic Aspects

All patients (100%) underwent conventional surgery using a conservative posterolateral thoracotomy of the chest wall muscles. The operative procedure was a perikystectomy in 33 patients (77%), a cystectomy in 7 patients (18%), and an atypical resection in 2 patients (5%). The postoperative operations were marked by the occurrence of a pyothorax in a single patient (hospitalization + chest drainage+ antibiotic therapy), a pneumothorax of great abundance in a single patient (chest drainage), and a hemo-pneumothorax in 2 patients (mobilization of the initial drain + in addition to a second chest drain). Anthelmintic therapy was indicated in 6 patients in this series (15%).

Discussion

Epidemiological Peculiarities

Hydatidosis is a parasitic pathology due to echinococcus granulosus which persists in Morocco always in endemic form [1]. The lung represents the first location in children, and the second location in adults after hepatic hydatidosis. Pleural hydatidosis remains the most frequent after pulmonary hydatidosis in terms of thoracic presentation [2].

Diagnostic Aspects

pleural hydatidosis is characterized by an it's location between the pulmonary fissures (large fissures or small fissure). The radiologic imaging can show that the hydatid cyst is fissural, but only the surgical exploration can make it possible to decide. This localization is a problematic diagnosis when the hydatid cyst is not ruptured, since it can be confused with encysted pleural effusion with interlobar development. The radiological picture in these cases is usually a rounded or oval lesion with well-defined liquid content. Fibroscopy is generally without particularity in hydatid cysts, especially on the periphery [3]. This fibroscopy aims to look for the presence of hydatid membranes, or otherwise looking for scolex in the fibroaspiration fluid. The presence of a bronchial fistula is rare due to the peripheral location of the cyst between the lobes.

Therapeutic Aspects

The management of the hydatid cyst is surgical. The basic intervention is based on a conservative treatment most often by perikystectomy. Sometimes when the cyst is large or ruptured with a non-functioning underlying lung, anatomical resection is essential [4], and in the most delicate cases, an atypical resection of the two lobes can be performed.

Conclusion

The hydatid cyst is a disease that is still a problem in Morocco. The fissural localization of the hydatid cysts is a diagnostic and therapeutic problematic that must be known by any thoracic surgeon.

References

1. M Bouchikh, Y Ouadnoui, M Smahi, Y Msougar, M Lakranbi, et al. (2008) Multiple extrapulmonary thoracic hydatidosis. *Respir Dis Rev* 25: 1110-4. (L'hydridose thoracique extrapulmonaire multiple. *Revue des maladies respiratoires*).
2. Oguzkaya F, Akçali Y, Kahraman C, Emirogullari N, Bilgin M (1997) Unusually Located Hydatid Cysts: intrathoracic but extrapulmonary. *Ann Thorac Surg* 64: 334-7.
3. N Moukram, N Zaghba, H Benjelloun, N Yassine (2017) Contribution of bronchoscopy in the diagnosis of pulmonary hydatid cyst. *Repir Dis Rev* 34: A101-2. (Apport de la bronchoscopie dans le diagnostic du kyste hydatique pulmonaire. *Revue des Maladies Respiratoires*).
4. Harmouchi H, Lakranbi M, Belliraj L, Ammor FZ, Issoufou I, et al. (2018) Indications of Anatomical Lung Resection in the Pulmonary Hydatid Cyst: About 21 Cases. *J Liver Clin Res* 5: 1048.