

Mixed Mullerian Tumors of the Ovaire: A Case Report

S Fajri*, Alexia ME, Ayoub A, Houssin B, Sakher M and Naima S

Gynecology and Obstetrics, Department of the Ibn Rochd Hospital, University Hospital Center Casablanca Morocco

***Corresponding author:** S Fajri, Gynecology and Obstetrics, Department of the Ibn Rochd Hospital, University Hospital Center Casablanca, Morocco, Tel: +21261817870, E-mail: safaa.fajri@gmail.com

Citation: S Fajri, Alexia ME, Ayoub A, Houssin B, Sakher M, et al. (2021) Mixed Mullerian Tumors of the Ovaire: A Case Report. SAJ Case Report 8: 201

Abstract

Ovarian carcinosarcoma (OSC), also known as mixed mesodermal tumor or mixed müllerian tumor, is a rare ovarian tumor, known to be highly aggressive representing less than 2% of ovarian cancers, it is characterized by the association of a carcinomatous component and a sarcomatous component. It is most often found in the uterus. It is rare to find it in the ovary. It often affects women between the ages of 60 and 70. Five-year survival ranges from 6 to 30%.

Keywords: Sanitation; Solid wastes; Liquid wastes; Informal settlements; Kigali city

Introduction

Rare type of cancerous (malignant) tumor made up of both epithelial cells (cells that make up the inner lining of hollow organs and glands in the body) and stromal cells (cells that make up the connective tissues that surround and support various organs in the body) [1].

A malignant mixed Müllerian tumor most often develops in the uterus (uterus), ovaries, or fallopian tubes (the conduit through which eggs are delivered from the ovary to the uterus) [2].

Ovarian carcinosarcoma (OSC) also known as mixed mesodermal tumor or mixed mullerian tumor, is a rare, aggressive, ovarian tumor that accounts for less than 2% of ovarian cancers. It is a most lethal gynecologic malignancy, largely due to the lack of effective screening strategies and diagnosis is usually made at an advanced stage. We report a case in a 65-year-old woman diagnosed and managed in the gynecology department at Ibn Rochd University Hospital in Casablanca.

Observation

Patient aged 65 years, mother of 1 child, without any particular pathological history, menopausal for 15 years, having presented with abdominal distension, the clinical examination objectified an abdomino-pelvic mass reaching the umbilicus. The radiological examination showed a voluminous pelvic-abdominal solid-cystic mass of 22x 12x 10 cm of probable ovarian origin, with CA-125: 149.37 IU/L.

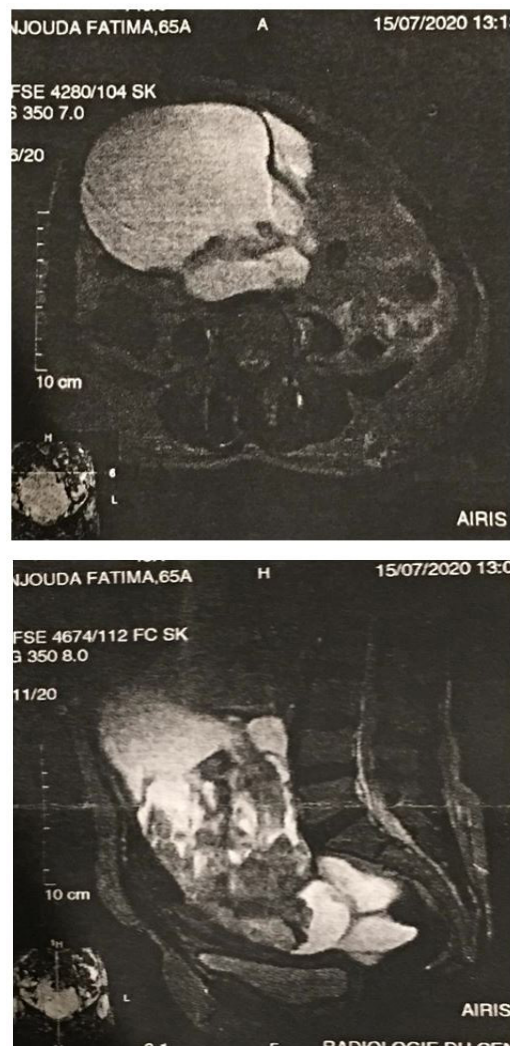


Figure 1: IRM image of the mass

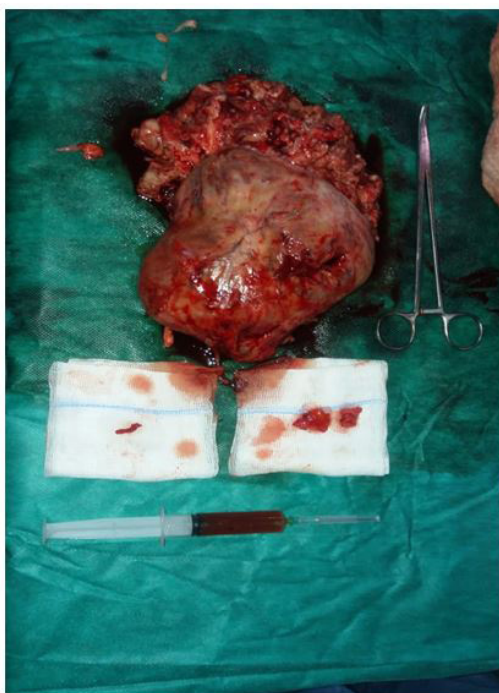


Figure 2: Tumor reduction specimen, biopsies and cytology

The patient underwent tumor reduction, epiploic and peritoneal biopsy + peritoneal cytology and was then referred to the oncology center where she was put on palliative chemotherapy with platinum salt and paclitaxel.

Discussion

Ovarian carcinosarcoma (OSC), also known as mixed mesodermal tumor or mixed müllerian tumor, is a rare ovarian tumor known to be highly aggressive. It represents less than 2% of ovarian cancers. It was Virchow in 1864, who was the first to use the name carcinosarcoma for the description of a tumor combining a component.

The clinical presentation of this pathology is non-specific. The most frequent symptom is abdominal distension. Abdominal pain, transit disorders, and an altered general condition may be associated. Apart from the transit disorders, these symptoms were present in our patient. Very often, the diagnosis is made at an advanced stage of the disease, which was the case in our patient because she already had peritoneal carcinosis [3].

This could be justified because carcinosarcomas are highly aggressive neoplasms that can be detected in many locations, mainly the female genital tract. Extragenital carcinosarcomas are extremely rare and mostly develop from the peritoneum, followed by the serosal surface of the colon, retroperitoneum, anterolateral abdominal peritoneum, and omentum. According to literature reviews, patients with primary peritoneal carcinosarcoma originating from the pelvic peritoneum or uterine serosa has better survival rate than that originating from other peritoneal surfaces.

Carcinosarcoma can be categorized as homologous or heterologous, depending on the histologic characteristics of the sarcomatous elements. Homologous carcinosarcomas have a sarcomatous component of fibrosarcoma, endometrial stromal sarcoma or leiomyosarcoma. Heterologous types include sarcomatous components that are made up of tissues non-native to the uterus such as malignant cartilage or skeletal muscle.

The metastatic locations are also not different from those of ovarian epithelial tumors. Amant and Eichhorn studied the value of CA125 in CS. It is increased in 75-85% of cases. Although not validated, it seems to be an interesting marker for therapeutic evaluation in the absence of clinical or radiological criteria [4].

The United States National Board of Oncology recommendations for the treatment of all-stage carcinosarcoma are to follow the guidelines for the Epithelial Ovarian Cancer, Fallopian Tube Cancer, and Primary Peritoneal Cancer group (briefly ovarian cancer, version 2.2015). In the same fashion are the guidelines of the European Oncology Community [9] and the German Society of Gynecological Oncology. Staging of the disease was performed according to TNM or FIGO criteria revised in 2009. The initial diagnostic approach includes patient history, physical examination, blood tests, tumor markers (CEA, CA -125) and in addition in the presence of prior histological confirmation: chest x-ray, mammography, gastroscopy and colonoscopy, ultrasound and / or computed tomography of the abdomen [5].

Due to the rarity of the disease, there is only limited data regarding the management of the disease. The key point of treatment is surgical debulking. However, most cases of carcinosarcoma have widely spread metastasis at the time of presentation, making optimal tumor debulking difficult [6].

For adjuvant treatment, the only published trial is that of Tate Thigpen for the Gynecologic Oncology Group (GOG). The substance used is cisplatin. The response rate is 20%, which is comparable to that seen in uterine SC. Given the low incidence of CSO, the implementation of therapeutic trials is difficult. The GOG proposes to extend the results already observed with uterine SC to OSC. Ifosfamide and cisplatin are, then, the two most interesting substances (doxorubicin having shown less efficacy in a GOG study on uterine sarcomas). For our patient, surgical excision was complete and chemotherapy was not indicated at her histological stage (PT1cN0). This was after a long discussion with the oncologists taking into account the poor sensitivity of SC to chemotherapy, not to mention that stage T1c requires chemotherapy in OCT. In the area of carcinosarcoma, there are no definitive results available from new prospective randomized studies to support specific guidelines for the diagnosis and treatment of the disease [10]. Phase III clinical trials specifically for ovarian carcinosarcoma are not currently being conducted, according to Clinicaltrials.gov. In several studies, however, patients with carcinosarcoma may also be included. A The phase 3 clinical study including cases of ovarian carcinosarcoma is GOG-0261. The study compares the efficacy of the combination with Paclitaxel Carboplatin versus the combination of Paclitaxel with Ifosfamide at all stages of the disease. The results of this study have not yet been published; According to the Clinicaltrials.gov website, the first month of completion for this study was November 2015. Several phase 1 and 2 clinical studies may recruit patients with ovarian carcinosarcoma. These studies seek the optimal combination of conventional chemotherapy, for example Carboplatin / Paclitaxel Gemcitabine, Paclitaxel / pegylated liposomal doxorubicin, pegylated liposomal carboplatin / doxorubicin, trabectedin or the optimal iv route of administration or Docetaxel / paclitaxel / carboplatin. Also, there are other phase 1 or 2 trials studying the effect of new targeted agents including mTOR inhibitors: temsirolimus, neoangiogenesis inhibitors (anti-VEGF): bevacizumab, zif-afibercept, sorafenib, sunitinib, PARP inhibitors eg. olaparib, verliparib, Aurora kinase inhibitors, eg alisertib and tyrosine kinase inhibitors, eg imatinib. However, in the near future there will be no new factors in the daily treatment of ovarian carcinosarcoma. There are other phase 1 or 2 trials studying the effect of new targeted observation is in favor of a heterologous CS of stage PT1cN0.

For the same stage, CS has a worse prognosis than OCT. Brown et al. seem to be the only ones to have compared these two tumors. They found a significant difference in median survival (8.2 versus 20.7 months, $p < 0.0001$)

Carcinosarcoma is an extremely rare tumor associated with a poor prognosis. Optimal surgical removal of the tumor mass and, where possible, macroscopically disease-free postoperative peritoneal cavity appear to have an important role in improving survival in these patients. Unfortunately, the existence of the sarcomatoid component limits the treatment options and prognosis of these patients. The need to improve the poor prognosis of these patients should prompt further multicenter studies and the introduction of new and experimental therapies.

Nevertheless, in various histological reports of carcinosarcoma, numerous targets have been identified, such as EGFR, c-Kit, Cox-2, Her-2-neu and VEGF. These molecules are currently under study and could offer future therapeutic prospects. Targeted therapies could probably find a place in future treatment options for this aggressive tumor, at least in the area of recurrence and conservation of the disease without chemotherapy. Current research efforts and clinical studies suggest a new therapeutic direction, despite poor results to date.

Conclusion

CS is a particular entity, rare, with a poor prognosis. Very few cases have been reported in the literature. Two histological types have been described: the heterologous type and the homologous type, but without any impact on the prognosis. Indeed, the only prognostic factor found in the various studies is the initial stage. Five-year survival is lower when compared to epithelial ovarian tumors. The lower sensitivity to chemotherapy gives surgery a primordial place, which should be as complete as possible.

References

1. M Muller, P-F Dupre, B Lucas, H Simon, J-P Malhaire (2007) Ovarian carcinosarcoma. *J Gynecol Obstet Biol Reprod* 36: 399-402.
2. A Bicher, C Levenback, E G Silva, T W Burke, M Morris, et al (1995) Ovarian malignant mixed müllerian tumors treated with platinum-based chemotherapy. *Obstet Gynecol* 85: 735-9.
3. Aliza L Leiser, Dennis S Chi, Nicole M Ishill, William P Tew, (2007) Carcinosarcoma of the ovary treated with platinum and taxane: The memorial Sloan-Kettering Cancer Center experience. *Gynecologic Oncology* 105: 657-61.
4. Rebecca Siegel, Elizabeth Ward, Otis Brawley, Ahmedin Jemal (2011) Cancer statistics, 2011: the impact of eliminating socioeconomic and racial disparities on premature cancer deaths. *CA Cancer J Clin* 61: 212-36.
5. K Berroho, A Achiq, A Fillali, L Elbarnoussi, MH Alami, et al. (2011) Ovarian carcinosarcoma: about a case report. *J Afr Cancer* 3:147-50.
6. G J Rustin, AE Nelstrop, P McClean, MF Brady, WP McGuire, et al (1996) Defining response of ovarian carcinoma to initial chemotherapy according to serum CA125. *J Clin Oncol* 14: 1545-51.
7. J Tate Thigpen, John A Blessing, Koen DeGeest, Katherine Y Look, Howard D Homesley, (2004) Cisplatin as initial chemotherapy in ovarian carcinosarcomas: a Gynecologic Oncology Group study. *Gynecol Oncol* 93: 336-9.
8. GP Sutton, JA Blessing, N Rosenshein, G Photopulos, PJ DiSaia (1989) Phase II trial for ifosfamide and mesna in mixed mesodermal tumors in the uterus. *Am J Obstet Gynecol* 161: 309-12.
9. Colombo N, Peiretti M, Garbi A, Carinelli S, Marini C, et al. (2012) ESMO Guidelines Working Group Nonepithelial Ovarian Cancer: ESMO Clinical Practice Guidelines for diagnosis, treatment and follow-up. *Ann Oncol* 23: 20–6.
10. Shylasree TS, Bryant A, Athavale R (2013) Chemotherapy and / or radiotherapy in combination with surgery for ovarian carcinosarcoma. *Cochrane Database System Rev* 2: CD006246.