

Light Bulb Sign

Desmercières J*, Schmutz T and Ribordy V

Emergency Department, Fribourg Hospital HFR, Villars-sur-Glâne, Switzerland

***Corresponding author:** Desmercières J, Emergency Department, Fribourg Hospital, Chemin des Pensionnats 2, 1708, Villars-sur-Glâne, Switzerland, Tel: +41798865196, E-mail: jdesmerc@msn.com

Citation: Desmercières J, Schmutz T, Ribordy V (2019) Light Bulb Sign. J Emerg Med Care 2: 101

Article history: Received: 28 March 2019, Accepted: 29 March 2019, Published: 01 July 2019

Clinical Image

A 50-year-old man consults emergency with functional impotence of the left shoulder following a violent fall. His examination finds an arm fixed in internal rotation with loss of external rotation. The X ray shows an internal rotation with rounding of the humeral head (sign of the bulb) signifying posterior dislocation (Figure 1A, circle). The CT scan for lesions associates with an inverse Hill-Sachs lesion (Figure 1B, arrow). Treatment consists of reduction under anesthesia followed by immobilization for 3 weeks. Posterior glenohumeral dislocation is rare, its diagnosis is difficult, often missed by lack of knowledge of subtle clinical and radiological signs. It is necessary to know to evoke it in front of an unexplained functional impotence of the shoulder following violent trauma or a tetanization (epilepsy, electrocution).

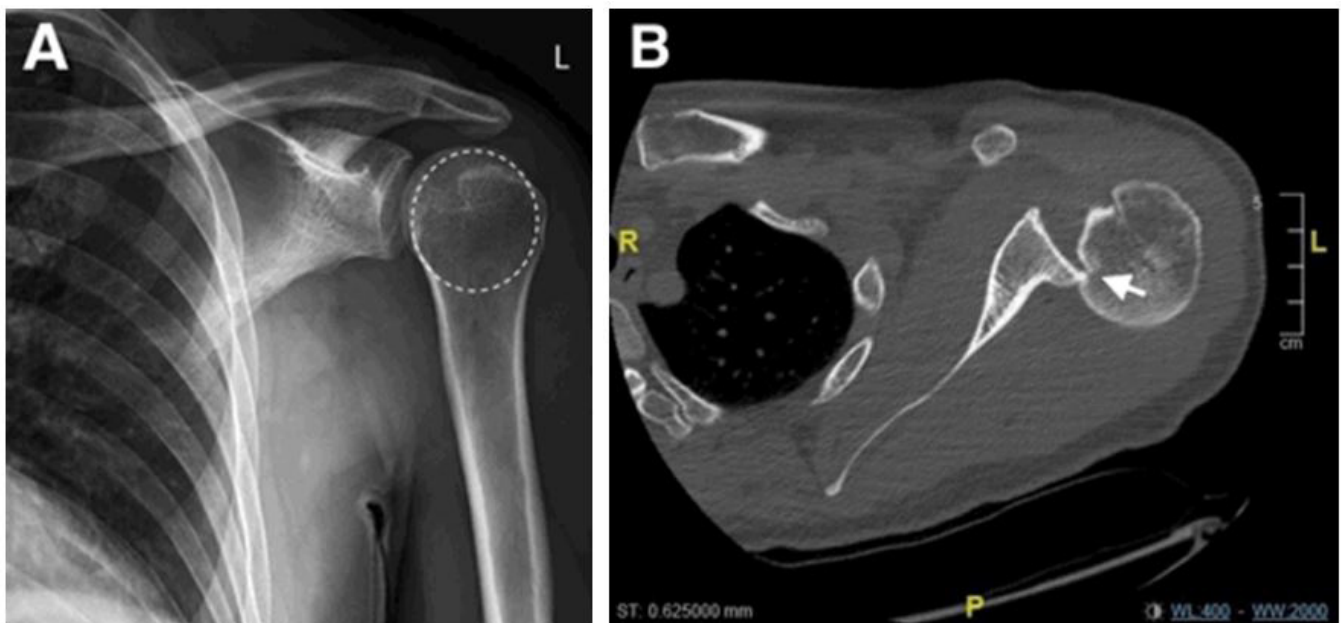


Figure 1: A. X-ray left shoulder incidence face objectifying an internal rotation of the humeral head (= sign of the bulb).
B. Shoulder CT scans showing reverse Hill-Sachs injury

References

1. Cunningham G, Hoffmeyer P (2011) Posterior dislocation of the shoulder, diagnostic and therapeutic challenges (Luxation postérieure de l'épaule, défis diagnostiques et thérapeutiques). Rev Med Suisse 7: 2489-93.
2. Ramsey ML, Klimkiewicz JJ (1999) Instability shoulder: diagnosis and management. Lippincott Williams Wilkins, London 295-7.
3. Robinson CM, Seah M, Akhtar MA (2011) The epidemiology, risk of recurrence, and functional outcome after an acute traumatic posterior dislocation of the shoulder. J Bone Joint surg Am 93: 1605-13