

CASE REPORT

Hypertriglyceridemia Induced Acute Pancreatitis: A Rare Cause

Singh B^{1*}, Dar AH¹, Khan AM², Shah HA², Ahmad N¹, Ashraf A¹ and Dahiya D³

¹Senior resident, Department of Gastroenterology, SKIMS, Srinagar, India

²Professor, Department of Gastroenterology, SKIMS, Srinagar, India

³Senior resident, Department of OBG & Pt.B.D, Sharma PGIMS Rohtak Haryana, India

***Corresponding author:** Singh B, Senior resident, Department of Gastroenterology, SKIMS, Srinagar, Jammu & Kashmir - 190011 India, Tel: +919416228718; E-mail: bhagat204@yahoo.com

Citation: Singh B, Dar AH, Khan AM, Shah HA, Ahmad N, et al. (2018) Hypertriglyceridemia Induced Acute Pancreatitis: A Rare Cause. J Pancreas Adv Res 1: 101

Abstract

Hypertriglyceridemia is not a common cause of acute pancreatitis. The risk begins to increase at triglyceride levels above 500 mg/dL. The clinical presentation is similar to other causes of acute pancreatitis. We hereby report the case of 40 years old male, known case of dyslipidemia presenting with first episode of AP.

Keywords: Hypertriglyceridemia; Acute Pancreatitis; Insulin; Amylase

Introduction

Hypertriglyceridemia is the third most common cause of acute pancreatitis (AP) after alcohol and gallstones. It is reported to cause 1 to 4 percent of all cases of AP and up to 56 percent of pancreatitis cases during pregnancy [1,2]. Hypertriglyceridemia (HTG) is considered a risk for pancreatitis when levels are >1000 mg/dL [3]. Moreover, there is 4% increase of incidental AP for every 100 mg/dL increase in TG concentration [4]. The clinical presentation of hypertriglyceridemic pancreatitis is similar to other causes of acute pancreatitis, but some evidences suggest that there may be an increased severity and risk of complications [5]. So, managing a patient of HTG induced pancreatitis is more challenging as compare to pancreatitis secondary to other etiologies. There are no definitive guidelines on the treatment of hypertriglyceridemia-induced pancreatitis (HTGP). Case series have suggested a role for insulin, heparin and plasmapheresis as adjunctive to conventional therapies such as statins and fibrates when treating HTGP [6]. Our case basically highlights the importance of spuriously normal levels of serum amylase with HTGP. So early clinical recognition of HTGP is extremely important to provide appropriate therapy and to prevent further episodes.

Case Report

A 40 years old male presented in emergency with chief complaints of epigastric pain radiating to back in a band-like fashion, which alleviated with bending forward and aggravated after meal, associated with vomiting and nausea for last 2 days. There was no history of fever, chills, jaundice, constipation, cough, and loss of consciousness, bleeding from any site, trauma, diabetes or thyroid disorders. Patient also gave history of dyslipidemia with poor compliance to treatment. Patient was non-smoker, non-alcoholic and had no similar episode in the past.

On examination, patient was oriented and hemodynamically stable but febrile to touch (temperature -100 °F) with tachypnea, tachycardia, low oxygen saturation (80%) on room air with decreased air entry in left infrascapular region and diffuse abdominal tenderness. No xanthelasmas, eruptions, arcus, or xanthomas were noted. Lab investigations revealed hemoglobin 18.6 (normal 13.5-17.5gm/dl) total leucocyte count 11,200 (normal 4,000 – 11,000/μl) platelet 161000 (normal 150,000 -450,000/μl) hematocrit 54% (normal 45%-52%). Differential leucocyte count revealed 84% neutrophils, 10% lymphocytes, 4% monocytes and 2% eosinophils. Serum electrolytes, thyroid function test, calcium, random blood sugar, liver function test, LDH and coagulation tests were normal. Serum creatinine was slightly deranged (1.4, normal 0.6-1.2 mg/dl) and arterial blood gas analysis was suggestive of hypoxemia. Serum amylase was normal on two occasions (44 U/l, 63 U/l; normal 40-139 U/l by IFCC reference method) but lipase was raised (312 U/l; normal 5-60 U/l by spectrophotometry). Chest x-ray was suggestive of bilateral pleural effusion and ultrasonography (USG) revealed normal gall bladder, bulky pancreas with peripancreatic fluid with free fluid in perisplenic region and left paracolic gutter.

In view of past history of dyslipidemia with normal amylase and USG suggestive of bulky pancreas, the possibility of HTG induced acute pancreatitis was kept. Lipid profile revealed very high serum triglyceride (TG) 4049 mg/dl (normal : less than 150 mg/dl), high cholesterol level 879 mg/dl (normal : less than 200 mg/dl) , high very low- density lipoprotein (VLDL) 130 mg/dl (normal 2-30 mg/dl) normal low-density lipoprotein 59 mg/dl and low high- density lipoprotein (HDL) 28 mg/dl (normal for men : 50-59 mg/dl). Serum was milky white after being left to stand overnight (Figure 1). Bedside index of severity in acute pancreatitis score was 3.

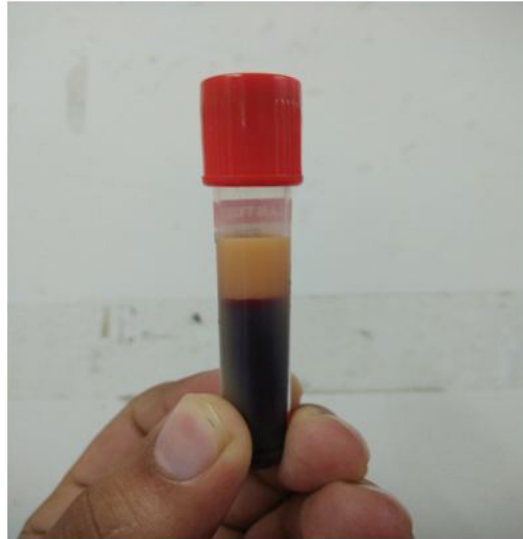

Figure 1: Milky white serum secondary to hypertriglyceridemia

Patient was conservatively managed with fluid resuscitation, O₂ inhalation, heparin, narcotics and antiemetics. He received insulin infusion 0.2 units /kg/hr alongwith dextrose. He did not receive any antibiotic for the first week. Contrast- enhanced computed tomography (CECT) abdomen was suggestive of bulky pancreas with peripancreatic fluid collection and fat stranding with free fluid seen in left paracolic gutter and left sided minimal pleural effusion. No area of necrosis was seen on CECT abdomen. Modified CT severity index was 6/10 (Figure 2).

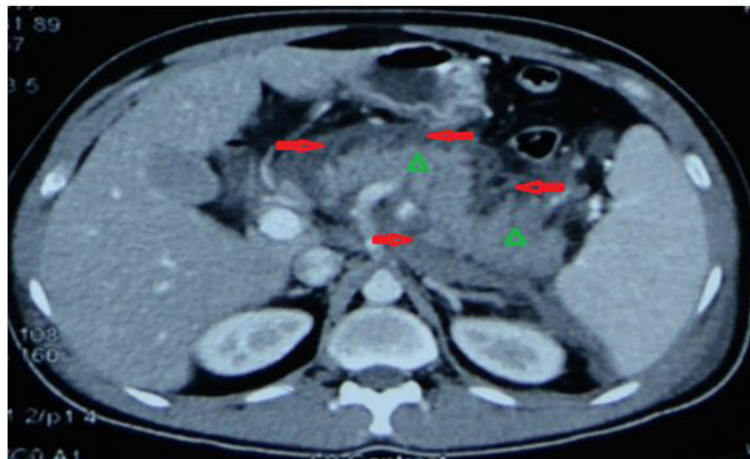


Figure 2: CECT abdomen showing homogenously enhancing bulky pancreas (arrow head) With peripancreatic fluid collection (arrow) and fat stranding

This treatment continued for 5 days with a follow-up of triglyceride level every day. Blood sugar monitored every 4 hour. Patient was continuously febrile, sick looking with high total leucocyte count 18,578 / μ l after first week of illness. Patient was empirically started on injection imipenem 500mg 8 hourly.

Blood culture was sterile. Antibiotics stopped after 2 weeks course. His triglyceride level was measured as 430 mg/dL on the 5th day of treatment. Patient was discharged on 20th day in stable condition.

Discussion

To diagnose HTGP on the basis of symptoms, physical examination and routine investigation (serum amylase, ultrasonography) is really a challenging one. On the basis of symptoms, signs and normal amylase value, we initially made the differential diagnoses of acute cholecystitis, cholangitis, acute mesenteric ischemia, perforated viscus with peritonitis and acute pancreatitis in resolving phase.

We subsequently then ruled out other conditions with the help of CECT abdomen, high serum lipase, high serum TG level, normal amylase and normal liver function tests. In view of high clinical suspicion (typical pancreatic type pain, milky white serum, history of dyslipidemia) and high TG levels with imaging findings of acute pancreatitis, we finally made the diagnosis of HTGP (Figure 2).

Pleural effusion has been observed in 4-20% of patients with AP [7]. Pleural effusion when present, are frequently small, left sided. In our patient, on presentation minimal bilateral pleural effusion was present which resolved as the severity of pancreatitis decreased. Two main mechanisms of pleural effusion development mentioned in the literature include transdiaphragmatic lymphatic blockage and pancreatice-pleural fistulae secondary to leak [8].

Triglycerides themselves do not appear to be toxic to pancreatic acinar cells. Rather, it is lipotoxicity of free fatty acids that are generated secondary to hydrolysis of triglycerides by pancreatic lipase [9]. Circulation of released excessive fatty acids increase the permeability of pancreatic acinar cells and capillary basal membranes resulting in emerged cytotoxic effects and induce pancreatitis.

Etiology of HTG can be primary (lipoprotein disorder) or secondary. Frederickson classification (lipoprotein disorder) types I (high chylomicrons), IV (high VLDL), and V (high chylomicrons and VLDL) are associated with severe HTG and predisposed to AP. Aquired causes of HTG includes uncontrolled diabetes, obesity, alcohol, hypothyroidism, pregnancy and drugs (clomiphene, protease inhibitors, antiretroviral agents, propofol, thiazide diuretics, and beta-blockers).

There are certain points that we should always keep in mind while dealing with a case of HTG induced pancreatitis. One, diagnostic dilemma as these patients can have normal amylase level because TG interferes with colorimetric analysis of amylase or an amylase inhibitor may be associated with TG elevation, similar to our case. Serial dilutions of the serum amylase sample can reduce the triglyceride interference. Other than amylase, LDL sodium & calcium can be falsely low [10,11].

Second, severity of AP caused by HTG is high because it depends on both the inflammatory response caused by pancreatitis itself, plus the injury caused by lipotoxicity from TG hydrolysis [12,13].

Third, regarding the management of HTG induced pancreatitis, as there are no fixed protocols that should be followed. Treatment modalities mentioned in the literature to control TG level in acute setting includes insulin infusion, heparin, plasmapheresis and fibrates.

Plasmapheresis is advised if patient has a serum triglyceride level >1000mg/dL plus lipase >3 times the upper limit of normal and signs of hypocalcemia, lactic acidosis, or signs of worsening inflammation or organ dysfunction, and if there are no contraindications to apheresis. Yeh, *et al.* found that a single exchange removed 66.3% of TG, while a second exchange removed 83.3% of serum TG [14].

If apheresis is unavailable or the patient cannot tolerate apheresis, or if the patient's serum glucose level is >500 mg/dl, intravenous infusion of regular insulin at a rate of 0.1 to 0.3 units/kg/hour is another option to decrease TG level. Insulin decreases hepatic production of apolipoprotein B-100 rich VLDL1 and intestinal production of VLDL2, rich in apoprotein B-48 while also increasing hydrolysis of TG by LPL [15].

Heparin infusion remains controversial in the treatment of HTGP. Heparin causes an initial rise in circulating lipoprotein lipase levels that is quickly followed by increased hepatic degradation of lipoprotein lipase [16]. This degradation contributes to further depletion of plasma stores of lipoprotein lipase and results in an increase of levels of chylomicrons.

According to ATP 3 guidelines, fibrates remain the drug of choice for severe HTG (TGs > 500 mg/dL) with niacin as adjunctive therapy [17]. Fibrates, statins, niacin, and omega three fatty acids have been shown to reduce TGs levels by 36.3%, 10% to 18%, 20%, and 25 to 33.8%, respectively [18-20].

Novel pharmacologic treatments for severe HTG have been described as mainly microsomal transfer protein (MTP) inhibitor Lomitapide and gene therapy for hereditary hypercholesterolemia and LPL deficient individuals [21]. Newer triglyceride-lowering modalities under evaluation and at different stages of development include gene therapy for lipoprotein lipase deficiency (alipogene tiparvovec, and antisense oligonucleotides against mRNA for apolipoproteins B (mipomersen) and C3 (volanesorsen, ISIS 304801), diacylglycerol acyltransferase-1 (pradigastat), and a monoclonal antibody against angiotensin-like protein 3 (REGN1500) [22]. There are existing data on biochemical efficacy but long term safety data is lacking.

We managed our patient with i.v infusion of insulin, subcutaneous heparin, fibrates and antibiotics in addition to conventional treatment of pancreatitis. Oral antihyperlipidemic agents and dietary fat restriction may be needed in long-term to prevent recurrences of AP and prevent other complications of HTG.

Conclusion

HTG induced pancreatitis is associated with diagnostic difficulty as these patients may have normal amylase level along with lack of suspicion for this etiology. To date, there are no official guidelines for the treatment of HTGP, although a number of different treatment modalities have been employed to rapidly lower the serum TG. Well designed, controlled, prospective studies are needed to clearly delineate the ideal regimen.

References

1. Fortson MR, Freedman SN, Webster PD (1995) Clinical assessment of hyperlipidemic Pancreatitis. *Am J Gastroenterol* 90: 2134-9.
2. Chang CC, Hsieh YY, Tsai HD, Yang TC, Yeh LS, et al. (1998) Acute pancreatitis in pregnancy. *Zhonghua Yi Xue Za Zhi (Taipei)* 61: 85-92.
3. Berglund L, Brunzell JD, Goldberg AC, Goldberg IJ, Sacks F, et al. (2012) Evaluation and treatment of hypertriglyceridemia: an Endocrine Society clinical practice guideline. *J Clin Endocrinol Metab* 97: 2969-89.
4. Murphy MJ, Sheng X, Macdonald TM, Wei L (2013) Hypertriglyceridemia and acute pancreatitis. *JAMA Internal Medicine* 173: 162-4
5. Scherer J, Singh VP, Pitchumoni CS, Yadav D (2014) Issues in hypertriglyceridemic pancreatitis: an update. *J Clin Gastroenterol* 48:195-203.
6. Fredrickson DS, Berger Z, Quera R, Poniachik J, Oksenberg D, et al. (2001) heparin and insulin treatment of acute pancreatitis caused by hypertriglyceridemia. Experience of 5 cases. *Revista medica de Chile* 129: 1373-8.
7. Heller SJ, Noordhoek E, Tenner SM, Ramagopal V, Abramowitz M, et al. (1997) Pleural effusion as a predictor of severity in acute pancreatitis. *Pancreas* 15: 222-5.
8. Maringhini A, Ciambra M, Patti R, Randazzo MA, Dardanoni G, et al. (1996) Ascites, pleural, and pericardial effusions in acute pancreatitis. A prospective study of incidence, natural history, and prognostic role. *Dig Dis Sci* 41: 848-52.
9. Navina S, Acharya C, DeLany JP, Orlichenko LS, Baty CJ, et al. (2011) Lipotoxicity causes multisystem organ failure and exacerbates acute pancreatitis in obesity. *Sci Transl Med* 3:107-10.
10. Howard JM, Reed J (1985) Pseudohyponatremia in acute hyperlipemic pancreatitis. A potential pitfall in therapy. *Arch Surg* 120: 1053-5.
11. Agarwal N, Pitchumoni CS, Sivaprasad AV (1990) Evaluating tests for acute pancreatitis. *Am J Gastroenterol* 85: 356-66.
12. Alagözlü H, Cindoruk M, Karakan T, UnalS (2006) Heparin and insulin in the treatment of hypertriglyceridemia-induced severe acute pancreatitis. *Dig Dis Sci* 51: 931-3.
13. Deng LH, Xue P, Xia Q, Yang XN, Wan MH (2008) Effect of admission hypertriglyceridemia on the episodes of severe acute pancreatitis. *World J Gastroenterol* 14: 4558-61.
14. Ewald N, Kloer HU (2009) severe hypertriglyceridemia: an indication for apheresis? *Atheroscler Suppl* 10: 49-52.
15. Pavlic M, Xiao C, Szeto L, Patterson BW, Lewis GF (2010) Insulin acutely inhibits Intestinal Lipoprotein secretion in humans in part by suppressing plasma free fatty acids. *Diabetes* 59: 580-7.
16. Näsström B, Olivecrona G, Olivecrona T, Stegmayr BG (2001) Lipoprotein lipase during continuous heparin infusion: tissue stores become partially depleted. *J Lab Clin Med* 138: 206-13.
17. Expert Panel on Detection, Evaluation, and Treatment of High Blood Cholesterol in Adults. (2001) Executive summary of the third report of the National Cholesterol Education Program (NCEP) expert panel on detection, evaluation, and treatment of high blood cholesterol in adults (adult treatment panel III). *J Amer Medi Assoc* 285: 2486-97.
18. Ito MK (2015) Long-chain omega-3 fatty acids, fibrates and niacin as therapeutic options in the Treatment of hypertriglyceridemia: A review of the literature. *Atherosclerosis* 242: 647-56.
19. Birjmohun RS, Hutten BA, Kastelein JJ, Stroes ES (2005) Efficacy and safety of high-density lipoprotein cholesterol-increasing compounds: A meta-analysis of randomized controlled trials. *J Am Coll Cardiol* 45: 185-97.
20. Harris WS (1997) n-3 fatty acids and serum lipoproteins: human studies. *Ame J Clinic Nutrition* 65: 1645S-54S.
21. Wetterau JR, Aggerbeck LP, Bouma ME, Eisenberg C, Munck A, et al. (1992) Absence of microsomal triglyceride transfer protein in individuals with abetalipoproteinemia. *Sci* 258: 999-1001.
22. Gryn SE, Hegele RA (2015) Novel therapeutics in hypertriglyceridemia. *Curr Opin Lipidol* 26: 484-91.