

Exclusive Radiotherapy for Pineal Parenchymal Tumor of Intermediate Differentiation: Case Report

Ait Erraisse M^{*}, Abboud FZ¹, Youssoufi MA², Alami B³, Bouhafa T¹ and Hassouni K¹

¹Department of Radiation Oncology, University Hospital Hassan II, Fez, Morocco

²Medical physics unit, University Hospital Hassan II, Fez, Morocco

³Department of Radiology, University Hospital Hassan II Fez, Morocco

***Corresponding author:** Ait Erraisse M, Department of Radiation Oncology, University Hospital Hassan II, Fez, Morocco; Tel: +212619948046, E-mail: aiterraissemohamed@gmail.com

Citation: Ait Erraisse M, Abboud FZ, Youssoufi MA, Alami B, Bouhafa T, et al. (2018) Exclusive Radiotherapy for Pineal Parenchymal Tumor of Intermediate Differentiation: Case Report. SAJ Case Rep 5: 404

Article history: Received: 20 August 2018, Accepted: 14 September 2018, Published: 17 September 2018

Abstract

Background and objectives: Pineal parenchymal tumor of intermediate differentiation (PPTID) are rare. treatment is mainly surgery but the real place of radiotherapy has not been established yet. The goal of this observation is to highlight the role of exclusive radiotherapy in management of these tumors.

The case: We report a case of a young woman diagnosed with PPTID after a biopsy following magnetic resonance imaging (MRI) showing the tumor after consultation for bilateral drop in visual acuity.

Results: An exclusive three dimensionnel conformal radiotherapy (3DCRT) was indicated because the tumor was unresectable. The follow up showed a clinical and radiological remission.

Conclusion: Although surgery is the main treatment for PPTID, radiotherapy could be a good alternative in the case of unresectable tumor or inoperable patient.

Keywords: Pineal Parenchymal Tumor; Intermediate Differentiation; Radiotherapy

Introduction

Pineal parenchymal tumor (PPT) is a rare tumor of the central nervous system accounting for less than 1% of all primitive CNS tumors [1]. Pineal parenchymal tumor of intermediate differentiation (PPTID) is a tumor with limited aggressive potential standing between the pineocytoma and pineoblastoma. PPTID was introduced into the world health organization (WHO) classification in 2007 as an intermediate-grade malignancy (Grade II or III) and constitutes approximately 10% of all pineal parenchymal tumors (PPT) [1]. Survival rates are better for PPTIDs than for pineoblastomas and also grade III had a much more aggressive biologic behavior compared with grade II [2,3,4]. Currently there is no a randomized controlled trial or systematic reviews assessing the effectiveness of surgical and non-surgical treatment. The treatment of choice is complete surgical resection. Adjuvant radiotherapy is indicated in partial resection or grade III tumors. Prophylactic cranio-spinal irradiation is controversial; the role of chemotherapy is uncertain. We describe a case of an unresectable PPTID that presented a good response to three-dimensional conformal radiation therapy (3DCRT), without recurrence or any adverse effects after 24-months follow-up.

The Case

This is a 21 years old female patient, single, with no particular medical history. The symptoms started 6 months earlier with headaches and vomiting. She received symptomatic medication from a general practitioner but with no improvement. She started having a decrease in her visual acuity and an increase in previous symptoms and then was referred to a neurologist. An MRI was indicated which showed the presence at the pineal region of a mixed multicomponent heterogenous mass measuring 36 x23mm, hyposignal on T2 weighted sequence, without translation on the diffusion sequence and without the signs of lesional bleeding. This process is heterogeneously enhanced delimiting multiple cystic chambers and a fleshy part. It compresses the fourth ventricle and leads to a moderate tri-ventricular dilation with sign of trans-ependymary resorption. The medial structures are in place. Arterial and venous MR angiography shows no abnormality. There was normal appearance of basal ganglia (Figure 1). A CT scan showed the same tumor with hydrocephaly.

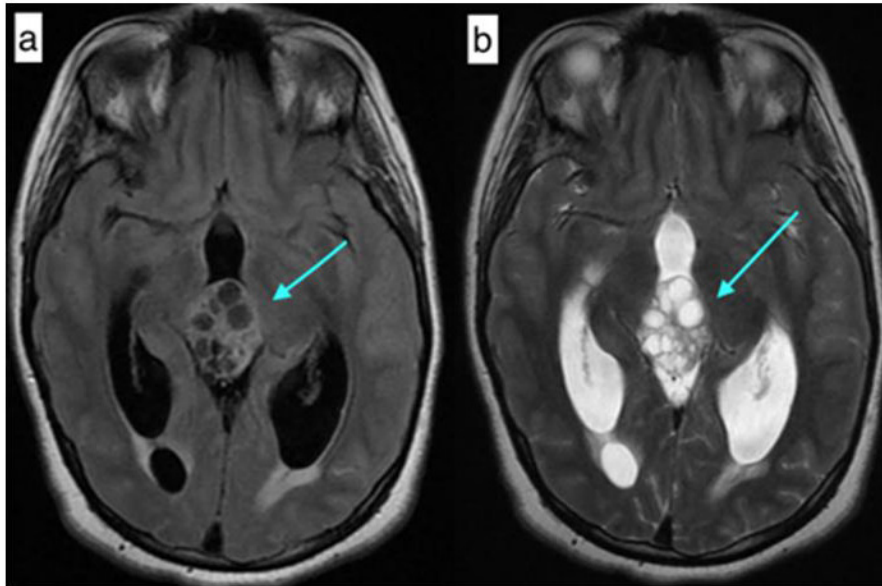


Figure 1: a- MRI T1 sequence with gadolinium injection b- T2 FLAIR sequence

The visual acuity dropped rapidly to a complete blindness. The neurosurgery team proceeded first with a stereotactic biopsy. The pathology report showed a pineal tumor with positive anti-cytokeratin. The Ki67 is at 5%. The number of mitoses is 5. The grade II or III couldn't be specified. They concluded to a pineal parenchymal tumor of intermediate differentiation (PPTID) according to WHO classification. The patient had a ventriculocisternostomy to alleviate the hydrocephaly (Figure 2).

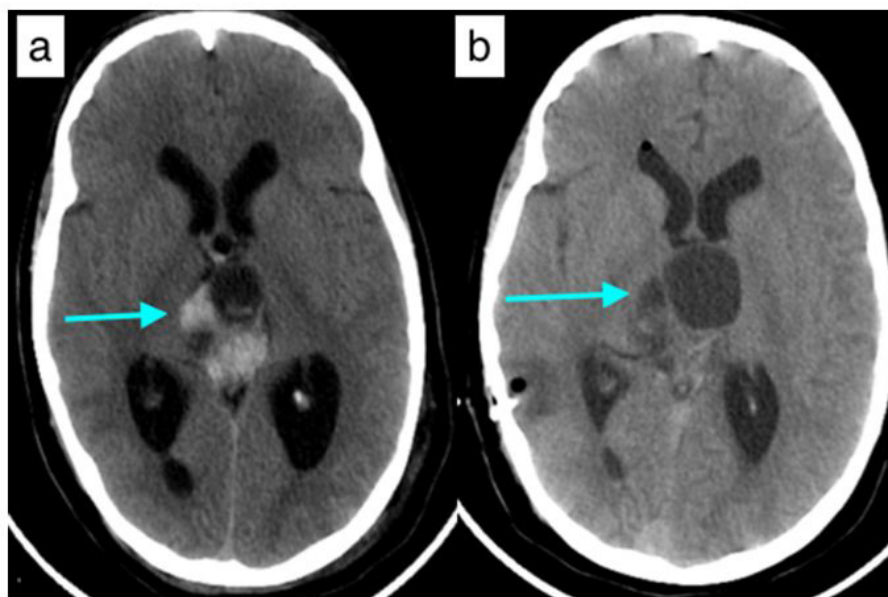


Figure 2: Axial CT scan slide showing the tumor with hydrocephaly (a) Post-derivation aspect without hydrocephaly (b)

The tumor was not respectable according to the neurosurgery team given the size and localization and the big risk of bleeding. The patient had neither more headaches nor vomiting, but the blindness remained. Ophthalmological evaluation showed complete drop in visual acuity, absence of photomotor reflex with papillary edema (due to tumor compression). A cerebrospinal MRI was made to look for potential nevrax metastasis, and no other lesion was found. After discussion of the case, an exclusive radiotherapy was indicated. She was referred to our department. At that time the tumor increased in size 45x31x47 mm. After CT simulation, countouring was made on CT/MRI fusion and then dosimetry for a 3D conformal radiotherapy. The CTV (clinical target volume) was made by adding 1 cm to the GTV (gross tumor volume). The PTV (planning target volume) was made by adding 0,5 cm to the CTV. The TPS (treatment planning system) used was Eclipse and the machine was LINAC Varian. We used 5 coplanar beams with X18 energy : 4 obliques with wedge on each one and one posterior. Beam angulations were 50, 130, 180, 230 and 310. The patient received a total dose to the tumor of 50 Gy, 2 Gy per fraction, 25 fractions on five weeks. The D90 was 100% of PTV. The maximal doses to the organs at risk were as follow : optic nerves (Right : 48,3 Gy, left : 47,2 Gy), optic chiasm (53 Gy), brainstem (52 Gy) and retinas (Right : 25,5 Gy; Left : 26,8 Gy) (Figure 3).

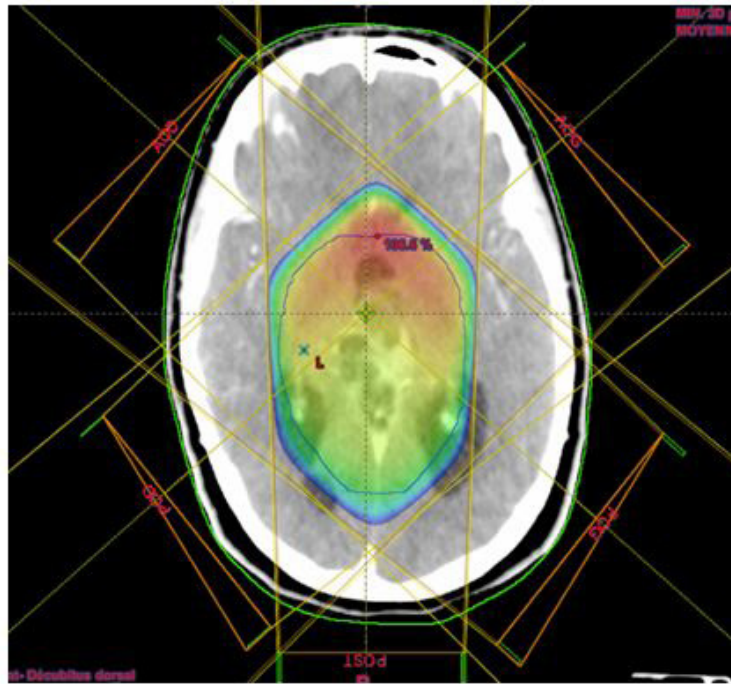


Figure 3: Dosimetric view with the isodose line conforming the target volume

Radiotherapy was well tolerated.

One month after radiation, the patient presented with the same initial symptomatology (headaches and vomiting). An MRI showed a moderate increase in tumor size with tri-ventricular hydrocephaly despite the ventriculocisternostomy. A ventriculo-peritoneal derivation was made and the patient was relieved. An MRI 4 months after radiation showed tumor size decrease by about 30 % (41x29x24 mm vs 47x45x31mm. The most recent MRI (after 20 months) showed a decrease by about 70 % (33x28x23 mm vs 47x45x31 mm (Figure 4).

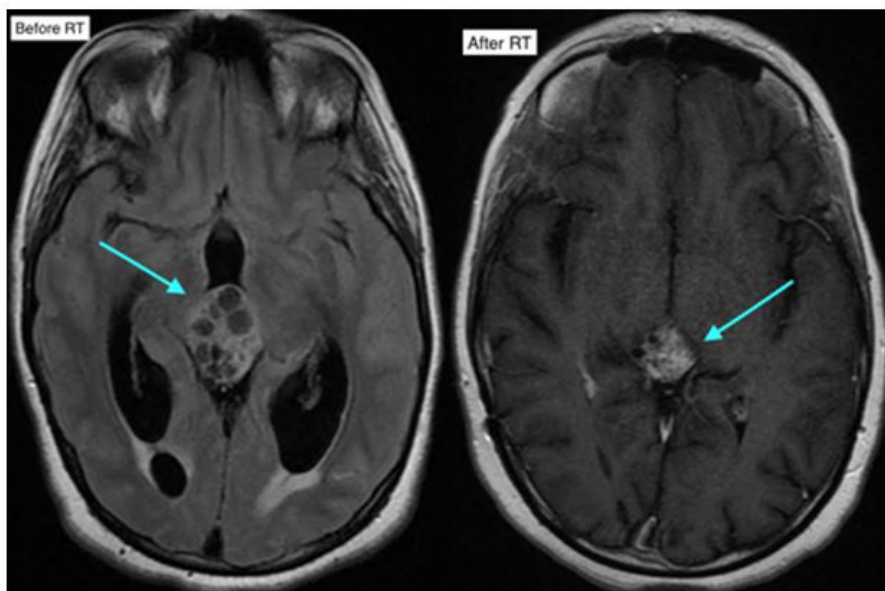


Figure 4: Control MRI after radiation with significant decrease in tumor size

During follow up, the patient got married and later she gave birth to a healthy baby boy. Despite the blindness, she keeps a good quality of life.

The follow up is 24 months with no signs of progression.

Discussion

In 2007, WHO classified pineal parenchymal tumors in three types: grade I or pineocytoma, grade II/III or PPTID and grade IV or pineoblastoma [5]. PPTIDs constitute approximately 10% of all PPTs [6]. PPTID occurs at all ages, from childhood to adulthood, with a peak incidence in early adults (mean: 38 years) [7]. There is a sharp female preponderance of these tumors and

they are more common in middle aged patients [8].

Symptoms at presentation vary according to the tumor aggressiveness and the most common are headache, vision abnormalities, nausea, vomiting. PPTIDs are usually heterogeneously hypointense on T1 weighted sequence and heterogeneously hyperintense on T2 weighted sequence, and show strong heterogeneous or uniform enhancement following gadolinium administration [9-11]. Histopathological confirmation is made either through stereotactic biopsy, endoscopic or open surgery. Jouvét, *et al.* proposed PPTIDs with less than six mitotic figures and presence of immunolabeling of neurofilament protein as grade II and more than six mitotic figures with loss of immunolabeling of neurofilament as grade III [1]. The surgery plays a pivotal role in relieving the local mass effect and providing a maximal tissue sample for histological analysis. Although gross total resection is associated with better local control, the correlation between the extent of resection and survival is not clear yet [12]. The good radiosensitivity of PPTs has already been reported [6,13]. Stereotactic radiosurgery is a valuable primary management modality for pinealocytoma; However, it may be used to boost therapy during multimodal therapy for malignant PPTs [14]. Local radiation may be preferred over craniospinal irradiation considering the toxicity associated. Though there is no consensus, a dose of 45–54Gy in conventional fractionation should be adequate. The association between radiation dose and survival outcome is also a matter of debate [15]. A study by Schild, *et al.* of 30 patients showed a link between the radiation dose and survival time in patients with pineal parenchymal tumours [16]. The higher rate of cerebro-spinal fluid (CSF) dissemination points toward importance of craniospinal radiation. Therefore, efforts should be made from clinical, pathological and genomic parameters to identify subgroup of patients at higher risk of leptomeningeal spread and intensify treatment accordingly [8]. In our case, the lumbar puncture was not performed, but the cerebro-spinal MRI showed no evidence of leptomeningeal dissemination, therefore radiotherapy was limited to the tumor. Three dimensional conformal radiotherapy (3DRCT) or intensity modulated radiotherapy (IMRT) are good techniques for these cases. Given the prescribed doses around 50 Gy, the dose constraints to organs at risk such as optic nerves, optic chiasm and brainstem can be respected. The role of chemotherapy still remains an area of conflict. Chemotherapy cannot be routinely recommended in adjuvant setting in patients with PPTID. It may be tried in patients with recurrent disease or those with cerebro spinal fluid dissemination. Prognosis factors according to different reports points towards complete surgical resection, tumor grade, tumor volume and residual tumor size after initial therapy [17]. In our case, the patient was young, the tumor was 45 mm at the time of radiotherapy. The grade could not be specified (II or III).

Conclusions

PPTID appear to be radiosensitive tumors, though the treatment of choice remains maximum safe resection. 3DCRT or IMRT can make a good alternative to surgery in case of unresectable tumor or inoperable patient. Cranio-spinal irradiation (CSI) and subsequent chemotherapy could be recommended to those with multiple lesions or CSF positivity. Given the rarity of this disease prospective multi-institutional studies should be arranged as soon as possible to establish the optimal PPTID management.

Acknowledgment

We acknowledge the pathology department (Pr Amarti) for her cooperation.

References

- Jouvét A, Saint-Pierre G, Fauchon F, Privat K, Bouffet E, et al. (2000) Pineal parenchymal tumors: a correlation of histological features with prognosis in 66 cases. *Brain Pathol Zurich Switz* 10: 49-60.
- Yi JW, Kim HJ, Choi YJ, Seol YM, Kahng DH, et al. (2013) Successful treatment by chemotherapy of pineal parenchymal tumor with intermediate differentiation: a case report. *Cancer Res Treat* 45: 244-9.
- Fauchon F, Jouvét A, Paquis P, Saint-Pierre G, Mottolese C, et al. (2000) Parenchymal pineal tumors: a clinicopathological study of 76 cases. *Int J Radiat Oncol Biol Phys* 46: 959-68.
- Lutterbach J, Fauchon F, Schild SE, Chang SM, Pagenstecher A, et al. (2002) Malignant pineal parenchymal tumors in adult patients: patterns of care and prognostic factors. *Neurosurgery* 51: 44-55.
- Louis DN, Ohgaki H, Wiestler OD, Cavenee WK, Burger PC, et al. (2007) The 2007 WHO classification of tumours of the central nervous system. *Acta Neuropathol* 114: 97-109.
- Anan M, Ishii K, Nakamura T, Yamashita M, Katayama S, et al. (2006) Postoperative adjuvant treatment for pineal parenchymal tumour of intermediate differentiation. *J Clin Neurosci Off J Neurosurg Soc Australas* 13: 965-8.
- Nakazato Y, Jouvét A, Scheithauer B (2007) Pineal parenchymal tumour of intermediate differentiation. In: Louis DN, Ohgaki H, Wiestler OD, eds. *WHO Classification of Tumours of the Central Nervous System*. 4th edn Lyon, France: IARC Press 124-5.
- Mallik S, Benson R, Rath GK (2016) Patterns of care and survival outcomes in patients with pineal parenchymal tumor of intermediate differentiation: An individual patient data analysis. *Radiother Oncol* 21: 204-8.
- Sato TS, Kirby PA, Buatti JM, Moritani T (2009) Papillary tumor of the pineal region: report of a rapidly progressive tumor with possible multicentric origin. *Pediatr Radiol* 39: 188.
- Banks KP, Brown SJ (2006) AJR teaching file: solid masses of the pineal region. *AJR Am J Roentgenol* 186: S233-5.
- Chang CG, Kageyama N, Kobayashi T, Yoshida J, Negoro M (1981) Pineal Tumors: clinical diagnosis, with special emphasis on the significance of pineal calcification. *Neurosurgery* 8: 656-68.
- Picarelli H, Savajoli JV, Feher O, Teixeira MJ (2016) Complete response to radiotherapy in a pineal parenchyma tumor of intermediate differentiation. *J Clin Case Rep* 6: 2.
- Stoiber EM, Schaible B, Herfarth K, Schulz-Ertner D, Huber P, et al. (2010) Long term outcome of adolescent and adult patients with pineal parenchymal tumors treated with fractionated radiotherapy between 1982. institution's experience. *Radiat Oncol* 5: 122.

14. Hasegawa T, Kondziolka D, Hadjipanayis CG, Flickinger JC, Lunsford LD (2002) The role of radio- surgery for the treatment of pineal parenchymal tumors. *Neurosurg* 51: 880-89.
15. Das P, Mckinstry S, Devadass A, Herron B, Conkey DS (2016) Are we over treating Pineal Parenchymal tumour with intermediate differentiation? Assessing the role of localised radiation therapy and literature review. *SpringerPlus* 5: 26.
16. Schild SE, Scheithauer BW, Haddock MG, Wong WW, Lyons MK, et al. (1996) Histologically confirmed pineal tumors and other germ cell tumors of the brain. *Cancer* 78: 2564-71.
17. Ito T, Kanno H, Sato K, Terasaka S, Hatanaka K et al. (2014) Clinicopathologic study of pineal parenchymal tumors of intermediate differentiation. *World Neurosurg* 81: 783-9.