

Erythematous Papules and Patches on the Hands

Aqil N*, Moustaide K and Mernissi FZ

Department of Dermatology, Hassan II University Hospital, Fes, Morocco

***Corresponding author:** Aqil N, Department of Dermatology, Hassan II University Hospital, Fes, Morocco, Tel: +212661328727, E-mail: niemaaqil90@gmail.com

Citation: Aqil N, Moustaide K, Mernissi FZ (2019) Erythematous Papules and Patches on the Hands. SAJ Case Report 6: 201

Article history: Received: 07 March 2019, Accepted: 08 April 2019, Published: 10 April 2019

Abstract

Erythema elevatum diutinum is a rare and chronic skin disorder. Clinically is characterized by red, purple, brown or yellow papules, plaques or nodules. These lesions are usually symmetrically distributed on the extensor surfaces of the extremities. Histologically, early lesions of erythema elevatum diutinum show leukocytoclastic vasculitis. We report a case of erythema elevatum diutinum in a pregnant woman. This patient is middle aged woman, with multiple pruritic lesions of the hands. After laboratory studies (erythrocyte sedimentation rate, C reactive protein, protein electrophoresis, serological test) and biopsy of lesions we confirmed a diagnosis of erythema elevatum diutinum. A paraclinical assessment of association with other diseases was made returning without abnormalities. Given localized lesions without systemic signs, the patient was started on topical corticosteroids with good progress until delivery, and remained in remission for two years.

Keywords: Erythema Elevatum Diutinum; Leukocytoclastic Vasculitis; Differential Diagnosis

Introduction

A 29-year-old woman, pregnant at 34 weeks of amenorrhea, presented with fixed, itchy and symmetric erythematous lesions on both hands, without other systemic signs or previous infection. The initial clinical examination revealed the presence of erythematous

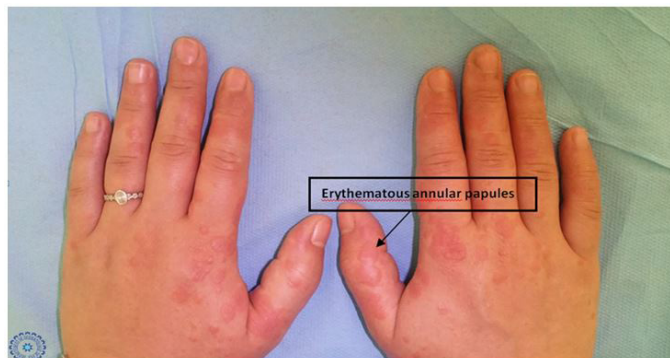


Figure 1A: Erythematous Annular Papules and Patches on the Dorsal Face Joints of the Hands

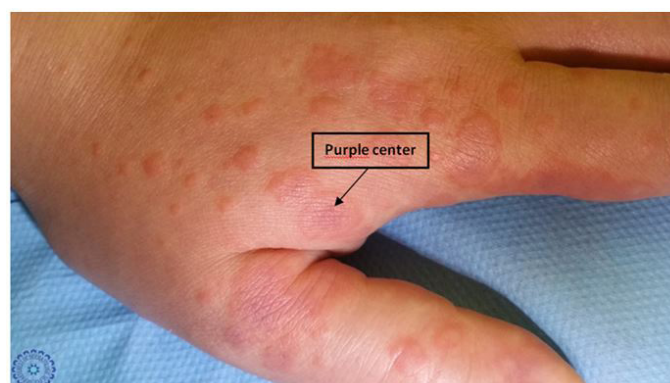

Figure 1B: Erythematous Annular Papules with a Purplish Center on the Dorsal Face of the Hand

papules and patches, with an infiltrated border and a depressed center giving an annular appearance, and others with a purplish, sometimes edematous center, on the dorsal aspect of both hands along with palmar involvement, in a symmetric manner (Figure 1A and 1B). There was no lymphadenopathy present. A skin biopsy from an erythematous infiltrated patch was obtained.

What is your Diagnosis?

- A. Granuloma annular
- B. Sweet syndrome
- C. Erythema Elevatum Diutinum
- D. Erythema multiform

Diagnosis

- C. Erythema Elevatum Diutinum

Microscopic Findings and Clinical Course: The biopsy specimen revealed an oedematous and slightly fibrous superficial reticular dermis, which contains inflammatory infiltrates arranged in perivascular cuffs essentially made of lymphocytes mixed with some histiocytes associated with some neutrophilic leucocytes with discrete leucocytoclasia. These elements penetrate the vascular wall. It associates discrete perivascular and parietal fibrinoid deposits (Figure 1C and 1D).

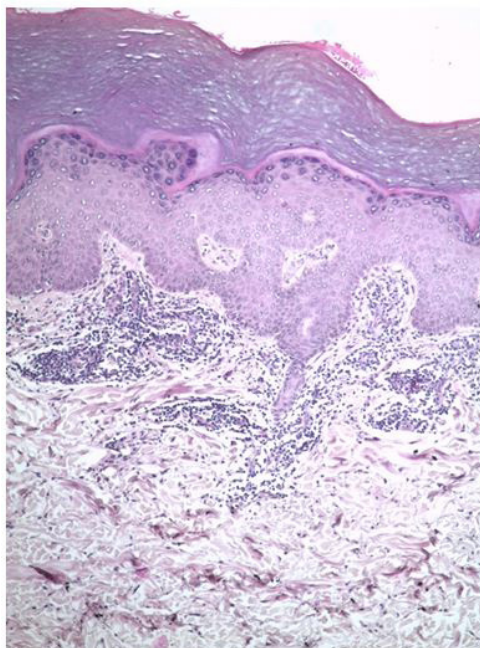


Figure 1C: A Punch Biopsy Specimen of a Plaque Showing Inflammatory Perivascular Infiltrate of the Superficial dermis (HES coloring G x 100)

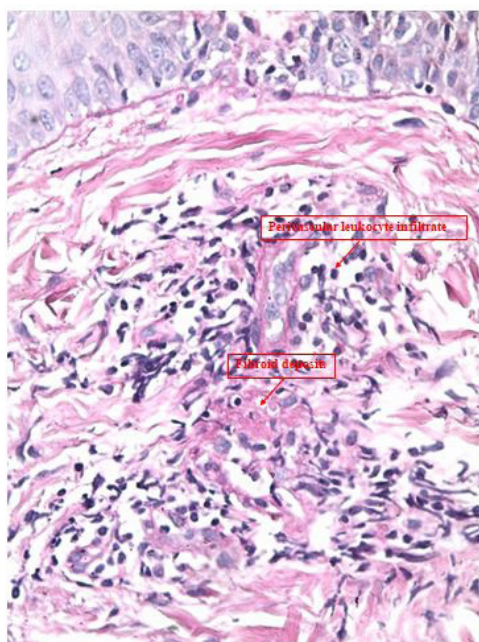


Figure 1D: This is the same Specimen at Greater Magnification (PAS coloring G x 400)

Clinicohistopathologic correlation supported the diagnosis of erythema elevatum diutinum (EED). A paraclinical assessment of association with other diseases was made returning without abnormalities. Given localized lesions without systemic signs, the patient was started on topical corticosteroids with good progress until delivery, and remained in remission for two years.

Discussion

Erythema Elevatum Diutinum (EED) is a rare and infrequent form of leukocytoclastic vasculitis. It is more frequent in adults between the third and sixth decades of life, presenting at any age [1]. It is most likely mediated by immune complexes, and is associated with autoimmune, neoplastic, hematological and infectious processes [2-4].

The lesions manifests as symmetrical, firm, yellow or pinkish to red, purple or brown papules, plaques or nodules on the backs of the hands, feet and extensor surfaces of the extremities overlying joints [5]. Although lesions are often asymptomatic, patients often experience pruritus, tenderness, and local burning sensation [4,6,7].

Histologically, the lesions are characterized by a leukocytoclastic vasculitis, with large endothelial edema in the small vessels of the upper and middle dermis, foci of fibrinoid degeneration called toxic hyaline of the vascular wall and a perivascular lymphocytic inflammatory infiltrate [8,9].

Clinicopathologic correlation is important for the diagnosis as EED lesions may sometimes mimic a variety of cutaneous diseases, such as Sweet syndrome, pyoderma gangrenosum, sarcoidosis, granuloma annulare and erythema multiforme [4,10].

The treatment of EED is difficult because of its chronic and recurrent course [11]. Dapsone is considered a first-line treatment for early lesions [7]. In the second line, colchicine, tetracycline and systemic steroids have been used with limited success [12]. The lesions of erythema elevatum diutinum resolved after one week of topical steroid use and remained in remission for one year [5]. As the case of our patient. In late lesions, the use of intralesional corticosteroids and surgical excision gave promising results [13]. Patients with underlying disorders or infections should benefit from targeted treatment of the underlying etiology, which could improve the results of EED [7].

Erythema Elevatum Diutinum is a rare chronic form of cutaneous vasculitis. It can imitate several pathologies. Although its cause is unknown, infections and systemic disorders associated with EED have been described: streptococcal infection, HIV infection, rheumatoid arthritis and monoclonal gammopathies. The association with pregnancy is very rare but can be explained by the fact that the latter is a temporary semi-allograft that survives for nine months, evolving favorably after delivery as is the case of our patient [14].

Consent for Publication

Written informed consent was obtained from the patient for publication of this case and any accompanying images. A copy of the written consent is available for review by the Editor-in-Chief of this journal.

Availability of Data and Material

Not applicable.

Competing Interests

The authors declare that they have no conflicts of interest.

Fundings

The authors declare no fundings.

References

1. Wilkinson SM, English JS, Smith NP, Wilson-Jones E, Winkelmann RK (1992) Erythema elevatum diutinum: A clinico pathological study. *Clin Exp Dermatol* 17: 87-93.
2. Rover PA, Bittencourt C, Discacciati MP, Zaniboni MC, Arruda LH, et al. (2005) Erythema elevatum diutinum as a first clinical manifestation for diagnosing HIV infection: case history. *Sao Paulo Med J* 123: 201-3.
3. Sharma V, Mahajan VK, Mehta KS, Chauhan PS, Chander B (2013) Erythema elevatum diutinum. *Indian J Dermatol Venereol Leprol* 79: 238-9.
4. García-Meléndez ME, Martínez-Cabrales SA, Eichelmann K, Gómez-Flores M, Ocampo-Candiani J (2015) Erythema elevatum diutinum: an atypical presentation. *Am J Med Sci* 349: 374-5.
5. Momen SE, Jorizzo J, Al-Niaimi F (2014) Erythema elevatum diutinum: a review of presentation and treatment. *J Eur Acad Dermatol Venereol* 28: 1594-602.
6. Yiannias JA, el-Azhary RA, Gibson LE. (1992) Erythema elevatum diutinum: a clinical and histopathologic study of 13 patients. *J Am Acad Dermatol* 26: 38-44.
7. Gibson LE, el-Azhary RA (2000) Erythema elevatum diutinum. *Clin Dermatol* 18: 295-9.
8. Requena L, Sanchez-Yus E, Martín L, Barat A, Arias D (1991) Erythema elevatum diutinum in a patient with acquired immunodeficiency syndrome. *Arch Dermatol* 127: 1819-22.
9. Kanitakis J, Cozzani E, Lyonnet S, Thivolet J (1993) Ultrastructural study of chronic lesions of erythema elevatum diutinum: extracellular cholesterolosis is misnomer. *J Am Acad Dermatol* 29: 363-7.

10. Wilkinson SM, English JS, Smith NP, Wilson-Jones E, Winkelmann RK (1992) Erythema elevatum diutinum: a clinicopathological study. *Clin Exp Dermatol* 17: 87-93.
11. Katz SI, Gallin JL, Hertz KC, Fauci AS, Lawley TJ (1977) Erythema elevatum diutinum: skin and systemic manifestations, immunologic studies, and successful treatment with dapsone. *Med* 56: 443-55.
12. Grabbe J, Haas N, Möller A, Henz BM (2000) Erythema elevatum diutinum-evidence for disease-dependent leucocyte alterations and response to dapsone. *Br J Dermatol* 143: 415-20.
13. Rinard JR, Mahabir RC, Greene JF, Grothaus P (2010) Successful surgical treatment of advanced erythema elevatum diutinum. *Can J Plast Surg* 18: 28-30.
14. Hanssens S, Salzet M, Vinatier D (2012) Immunological aspects of pregnancy (Aspects immunologiques de la grossesse). *Journal de Gynécologie Obstétrique et Biologie de la Reproduction* 41: 595-611.