

CASE REPORT

Diabetic Striatopathy Associated with Type 2 Diabetes: A Rare Complication

Shahzad W^{1*}, Inayat T², Syed F², Arif MA², Hassan M¹, Rajput HM¹ and Badshah M¹

¹Department of Neurology, Shaheed Zulfiqar Ali Bhutto Medical University, PIMS, Islamabad, Pakistan

²Department of Medicine, Shaheed Zulfiqar Ali Bhutto Medical University, PIMS, Islamabad, Pakistan

***Corresponding author:** Shahzad W, Department of Neurology, Shaheed Zulfiqar Ali Bhutto Medical University, PIMS, Islamabad, Pakistan, Tel: +923015165060, E-mail: valeed@live.com

Citation: Shahzad W, Inayat T, Syed F, Arif MA, Hassan M, et al. (2020) Diabetic Striatopathy Associated with Type 2 Diabetes: A Rare Complication. J Diabetic Complications Res 1: 104

Abstract

Diabetic hemi-chorea/hemi-ballism is a spectrum of hyper kinetic involuntary, non-patterned, continuous movements involving one side of the body. It involves contra lateral basal-ganglia and often striatum in the brain. Here we are reporting an un-usual case of choreiform movement disorder which was sudden in onset. It was accompanied with abnormally high values of blood glucose. Our patient had a complete remission of symptoms after an adequate control of blood glucose was achieved. This case illustrates the importance and rarity of having the knowledge about hyperglycemia as a rare cause of hemi-chorea as it recovers rapidly with a good prognosis. Screening for hyperglycemia even in those patients without a prior history of diabetes is very important, once they present with an involuntary movement disorder. Recognition and early treatment is beneficial to prevent adverse outcomes. Today, in the medical literature it is often referred to as C-H-B-G (chorea, hyperglycemia, basal ganglia) syndrome.

Keywords: Diabetic Hemi-Chorea; Choreiform Movement Disorder; C-H-B-G Syndrome

Introduction

Hyper osmolar non-ketotic syndrome is a clinical syndrome of hyperglycemia, hyper-osmolarity and dehydration without keto acidosis [1]. Hemi-chorea is an involuntary, continuous, non-patterned, irregular and non-rhythmic movement involving one side of the body due to lesions found in the contra lateral striatum. Ballism is rhythmic, varying and large-amplitude involuntary movement predominantly affecting the proximal extremities. Hemi-ballism are involuntary flailing type of movements of one side of the body resulting in lesions in the contra lateral sub-thalamic nucleus. Therefore, hemichorea-hemi ballism (HCHB) is a clinical spectrum of continuous, in-voluntary and non pattered movements that involve one side of the body. Hemi-ballism develops gradually into hemi-chorea. The possible causes consist of ischemic or hemorrhagic stroke, Central-nervous-system neoplasms, systemic lupus erythematosus (SLE), Hyperglycaemic-Hyperosmolar-Nonketotic-Coma (HONK), Wilson's disease & thyro-toxicosis [2]. Recent epidemiology suggests that elderly Asian females are more affected which implicates an underlying genetic predisposition [3].

Females being more affected could be related to post-menopausal estrogen induced alterations of mainly two inhibitory neuro transmitters: Gamma-Amino-Butyric-Acid (GABA) or dopamine [4]. The patho physiology is not fully understood and there are many conflicting theories. Hyperglycemia hampers cerebral auto-regulation causing hypo perfusion resulting in anaerobic metabolism leading to depletion of inhibitory GABA transmitters in basal ganglia causing involuntary movements [5,6]. Hyper viscosity due to hyperglycemia disrupts blood-brain-barrier which leads to vascular compromise of the striatal- neurons [7]. This produces a synergistic effect of uncontrolled hyperglycemia and vascular destitution causing dysfunction of the striatum leading to irregular movements [8]. Histo-pathology findings in such patients have shown gliosis and neuronal loss without evidence of infarction or hemorrhage at striatum [8].

Case Presentation

A man in his late 50's with type 2 diabetes for more than 10 years presented with two days history of involuntary and sudden onset un-patterned movements involving left side of the body. He had chore form movements of left upper extremity that were not under voluntary control, couldn't be suppressed but stopped during sleep. These movements were not associated with tongue bite, upward eye rolling, lateral rotation of the neck, frothing from mouth or sphincter incontinence. Previously he didn't have history of stroke

or trauma. He had no significant drug addiction or family history of any disease. Huntington's disease was excluded since his age didn't fit the usual age of the disease. His dietary patterns included a carbohydrate rich diet, a sedentary life style & showed poor compliance to anti-diabetic drugs. He was overweight, having truncal obesity and a body mass index of 29. On examination he was conscious and alert with normal higher mental functions. Cranial nerves were normal. His pupils were 3mm bilaterally reactive to light. No motor or sensory deficits were found. No loss of power, muscle strength or tremors was observed. Babinski sign was negative. His gait was normal. Cerebellar signs were intact and had no signs of meningeal irritation.

His vital signs were normal. Initial bio-chemistry showed random serum glucose of 544mg/dL, a venous pH of 7.38. Urinary ketones were negative. Serum ketones were 0.4mmol/L (range 0.1 - 0.6mmol/L). Serum potassium 3.6mg/dL while serum sodium was 138mg/dL. Patient's HbA1c on last OPD visit was 12.1%. Anti dsDNA antibodies were 2 IU/ml (range 104 IU/ml) ANA & ENA profiles were negative. Serum TSH was 1.9 ng/dL (range 1.8-3.0 ng/dL) while FT4 was 1.2 ng/dL (range 1.0-1.53 ng/dL). His lipid profile was abnormal and showed a total cholesterol of 248 mg/dL, low-density lipoprotein level of 166 mg/dL, triglycerides level of 200 mg/dL, and a high-density lipoprotein level of 38 mg/dL. Imaging of the carotid arteries revealed a normal internal carotid artery to common carotid artery ratio with no significant stenosis. Electro-encephalogram (EEG) showed normal alpha activity with no focal, diffuse or generalized abnormality. Echocardiogram showed no valvular abnormality with an ejection fraction of 65%. Extended work up for Wilson's disease revealed no abnormalities. Slit-lamp examination of the eyes showed no Kayser-Fleischer rings.

Serum ceruloplasmin levels were 28 mg/dL (range 20-35 mg/dL). 24 hour urinary free copper levels were 15 ug/24 hours (range 10-30 ug). Chest Xray and electrocardiogram (ECG) showed no abnormalities. Computed tomography (CT) of the brain revealed no evidence of any acute intra cranial pathology (Figure 1). Cerebro vascular accident was excluded as there was no focal neurological deficit except involuntary movements. MRI Brain showed a T1 asymmetric hyper intensity of the right putamen (Figure 2). During hospitalization strict blood glucose monitoring was initiated. Insulin was started on sliding scale and levels were maintained between 80 to 120 mg/dL. Oral administration of Haloperidol 0.5mg twice daily was started which showed no response. Dose was gradually increased to 1mg twice a day. By the 8th day, his un-controlled & in-voluntary movements were alleviated. He was discharged on 10th hospital day on haloperidol 1mg twice daily, rosuvastatin 10mg at night and a strict insulin regimen. During his follow up after 2 months his chorei-form movements had completely resolved. His HbA1c of 8.5 % showed an adequate diabetic control.

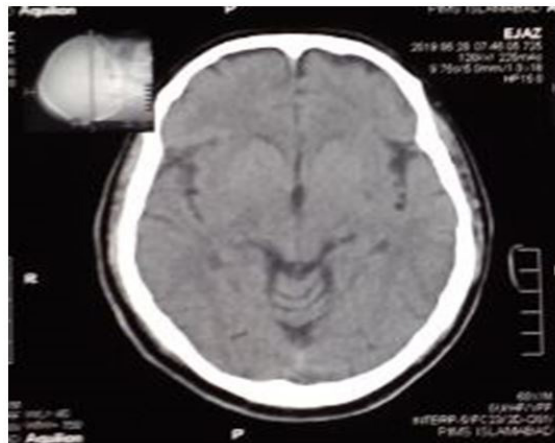


Figure 1: Normal CT Brain

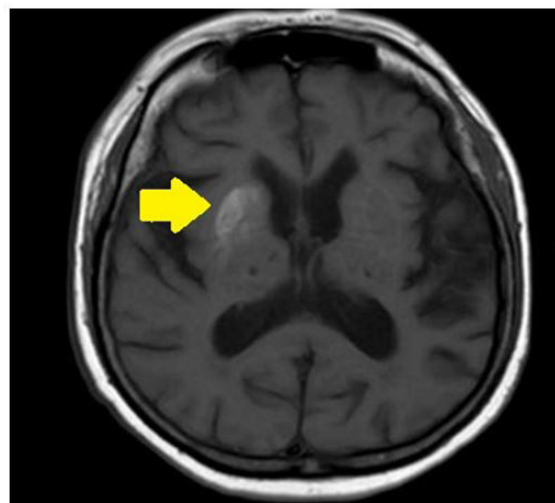


Figure 2: MRI Brain Showing T1 Hyper intensity of Right Putamen

Discussion

In our case the diagnosis of diabetic striatopathy was made with typical clinical as well as radiological manifestations which included ballistic-choreiform movements together with hyperglycemia in the absence of keto-acidosis. In the literature, it has been proposed that T1 hyper-intensity could be due to partial ischemic insult secondary to hyper viscosity which is caused by prolonged hyperglycemic states ; in turn disrupting the blood-brain-barrier leading to vascular compromise of the functioning striatal-neurons leading to their death [9]. Hyper glycemia also hampers cerebral auto-regulation causing hypo perfusion resulting in anaerobic metabolism leading to depletion of GABA inhibitory transmitters in basal ganglia leading to involuntary movements [5,6]. In patients with poorly controlled diabetes mellitus certain metabolic disturbances are associated with hyper-glycemia along with vascular insufficiencies which together contribute to regional metabolic failure in the brain. This in turn produces ischemic/hypoxic damage leading to metabolic derangement causing rapid escalation of swollen astrocytes known as gemistocytes [9].

Hemi-chorea/hemi-ballismus may occur in patients already known to be diabetics [10] or it may be the first manifestation of the disease [10]. Neuro-radiological findings are consistent with hemi chorea and a non- ketotic hyperglycemic state. A T1 weighted hyper-intensity is seen in the striatum/globus pallidus on MRI brain. Restricted diffusion is seen on diffusion-weighted-image (DWI) [11]. Magnetic-resonance-spectroscopy may reveal low levels of N-acetyl-aspartate to the ratio of creatinine. There is a high-choline ratio often showing lactate peak, signifying dysfunction, damage or loss of neurons [12].

Literature shows that hemi chorea resolves once the serum glucose levels are controlled and can be treated actively [13]. The onset of chorea often coincides with the severity of hyper-glycemia and has a temporal relation with blood glucose levels coming to normal thus showing resolution of involuntary choreiform movements [14]. The mainstay of treatment is aggressive glucose control with resolution of abnormal movements [15]. There is an improvement in radiological signs on MRI brain that usually take 6 months to vanish once glycemic levels are controlled. In a few refractory-cases an additional medication like halo-peridol, tetrabenazine or resperidone has been documented to improve these movements. Our patient showed a considerable improvement of his symptoms with adequate treatment which is consistent with the literature highlighting typical and atypical findings in this rare presentation.

Conclusion

This clinico radiological phenomenon deserves attention because it is rapidly improved with a good prognosis once hyper-glycemia is corrected. Screening for hyper-glycemia even in those patients without a prior history of diabetes is very important, once they present with an involuntary movement disorder. Recognition and treatment is beneficial to prevent adverse outcomes.

References

1. Qi X, Yan Y, Gao Y, Zheng Z, Chang Y (2012) Hemichorea associated with non-ketotic hyperglycaemia: a case report. *Diabetes Res Clin Pract* 95: e1-e3.
2. Padmanabhan S, Zagami AS, Poynten AM (2013) A case of hemichorea-hemiballismus due to nonketotic hyperglycemia. *Diabetes Care* 36: e55-6.
3. Mittal P (2011) Hemichorea-hemiballism syndrome: a look through susceptibility weighted imaging. *Ann Indian Acad Neurol* 14: 124-26.
4. Battisi C, Forte F, Rubenni E, Dotti MT, Bartali A, et al. (2009) Two cases of hemichorea-hemiballism with nonketotic hyperglycemia: a new point of view. *Neurol Sci* 30: 179-83.
5. Nath J, Jambherkar K, Rao C, Armitano E (2006) Radiological and pathological changes in hemiballism-hemichorea with striatal hyperintensity. *J Magn Reson Imaging* 23: 564-68.
6. Cheema H, Federman D, Kam A (2011) Hemichorea-hemiballismus in non-ketotic hyperglycaemia. *J Clin Neurosci* 18: 293-94.
7. Slabu H, SAVEDIA-CAYABYAB S, Senior P, Arnason T (2011) Permanent haemichorea associated with transient hyperglycemia. *BMJ Case Rep*.
8. Lin JJ (2001) Ipsilateral putamen hyperintensity on T1-weighted MRI in non-ketotic hyperglycemia with hemiballism-hemichorea: a case report. *Parkinsonism Relat Disord* 7: 319-21.
9. Higa M, Kaneko Y, Inokuchi T (2004) Two cases of hyperglycaemic chorea in diabetic patients. *Diabet Med* 21:196-8.
10. Shan DE, Ho DM, Chang C, Pan HC, Teng MM (1998) Hemichorea-hemiballism: an explanation for MR signal changes. *Am J Neuroradiol* 19: 863-70.
11. Zaitout Z (2012) CT and MRI findings in the basal ganglia in non-ketotic hyperglycaemia associated hemichorea and hemi-ballismus (HC-HB). *Neuroradiol* 54: 1119-20.
12. Narayanan S (2012) Hyperglycemia-induced hemiballismus hemichorea: a case report and brief review of the literature. *J Emerg Med* 43: 442-4.
13. Taboada GF, Lima GA, Castro JE, Liberato B (2013) Dyskinesia associated with hyperglycemia and basal ganglia hyperintensity: report of a rare diabetic complication. *Metab Brain Dis* 28: 107-10.
14. Oh SH, Lee KY, Im JH, Lee MS (2002) Chorea associated with non-ketotic hyperglycemia and hyperintensity basal ganglia lesion on T1-weighted brain MRI study: a meta-analysis of 53 cases including four present cases. *J Neurol Sci* 200: 57-62.
15. Hwang KJ, Hong IK, Ahn TB, et al. (2013) Cortical hemichorea-hemiballism. *J Neurol* 260: 2986-92.