

# Cephalometric Changes after Orthodontic Treatment and Fixed Oral Rehabilitation in Adult Patients: 23 Years of Follow-Up

Kulmer S<sup>1\*</sup>, Hattmannstorfer R<sup>2</sup>, Niedermoser A<sup>2</sup>, Richter M<sup>3</sup> and Brandstatter A<sup>4</sup>

<sup>1</sup>Medical University Innsbruck, Innsbruck, Austria

<sup>2</sup>Private Practice, Innsbruck, Austria

<sup>3</sup>Professor and chairman, Clinical Department of Orthodontics, Innsbruck Medical University, Austria

<sup>4</sup>Division of Genetic Epidemiology, Department of Medical Genetics, Clinical and Molecular Pharmacology, Innsbruck Medical University, Austria

\*Corresponding author: Kulmer S, Medical University Innsbruck, Innsbruck, Austria, Tel: +43512377087, E-mail: rs-kulmer@aon.at

**Citation:** Kulmer S, Hattmannstorfer R, Niedermoser A, Richter M, Brandstatter A (2019) Cephalometric Changes After Orthodontic Treatment and Fixed Oral Rehabilitation in Adult Patients: 23 Years of Follow-Up. J Oral Health Dent Sci 3: 402

**Article history:** Received: 19 August 2019, Accepted: 09 October 2019, Published: 22 October 2019

## Abstract

The aim of the present study was to investigate the long-term changes of craniofacial structures, teeth and soft-tissues after extended fixed oral rehabilitation over a period of 23 years.

**Materials and Methods:** A total of 15 selected patients (13 women, 2 men; mean age 42.04±10.05 years) obtained extended fixed dental restorations by utilization of the principles of the occlusal concept of sequential guidance with front-canine-dominance. The measurements were based on lateral cephalometric roentgenograms which were taken shortly, 10, 15 and 23 years after dental rehabilitation of each participant of the study. The lateral roentgenograms were traced and distances were measured with a digital calliper.

**Results:** The data showed an increase of 2.67 mm of the lower face height (PP-Me), the distance between the palatal plane and the incisal edge of the upper central incisor (PP-Is) increases by 1.49 mm, implying a downward movement of the upper incisors. Corresponding to these changes in the upper jaw, the distance from palatal plane to the incisal edge of the lower central incisor increases by 1.10 mm, vertical overbite increases by 0.39 mm, and the distance between Sella and Gnathion increases by 4.99 mm. The lip seal slides downward by 3.31 mm on average over 23 years after rehabilitation.

**Conclusion:** Significant changes in the lower face can be estimated which are in harmonious accord with the natural changes in the adult aging craniofacial complex.

**Keywords:** Occlusion; Long-term changes in craniofacial structures

**Abbreviations:** PP-Me: Distance from palatal plane to menton; PP-Is: Distance from palatal plane to upper central incisor; PP-Li: Distance from palatal plane to lower central incisor; PP-LS: Distance from palatal plane to lip seal; PP-IP (%): Distance from palatal plane to an individual point in the molar region of the lower jaw (calculated as a percentage); VOL: Vertical overlap / PP-Is to PP-Li; LS-Me: Distance from lip seal to menton; LS-Is: Distance from lip seal to upper central incisor; LS-Li: Distance from lip seal to lower central incisor; S-Gn: Distance from sella to gnathion

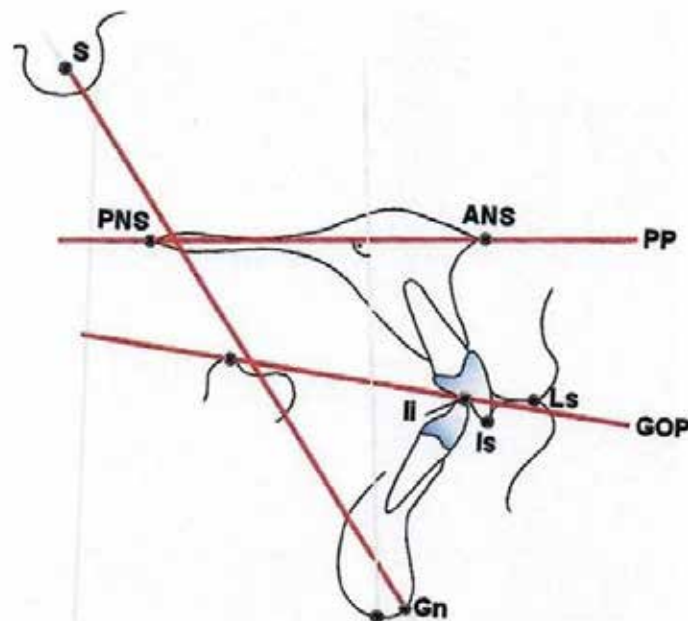
## Introduction

Oral rehabilitation has to fulfill high claims to aesthetics and function but also should provide long-term stability. If an extended fixed dental rehabilitation is planned a detailed diagnosis including cast and clinical functional analysis, axiography, muscle and temporomandibular joint (TMJ) evaluation, cephalometric analysis, and a careful treatment planning is essential [1-5]. Fixed dental rehabilitation includes the adjustment of centric occlusion in accordance with centric relation of the temporomandibular joint and individual calculation of cusp inclines and condylar path inclination. Based on these information an optimized construction of the guiding elements of the restoration can be created, which is best possible carried out by the occlusal concept of sequential guidance with front-canine-dominance [1-3,6]. This anterior posterior sequence of the occlusal guiding elements ensures the least muscular activity [3,7-10] and provides atraumatic and safe function of the stomatognathic system and should guarantee stability. Looked at from this point of view the patients for the present study were selected and rehabilitated with consideration for the above mentioned factors to create the best possible occlusion and function for each individual patient. The purpose of our study was to investigate the cephalometric changes in the dentofacial complex 10, 15 and 23 years after dental rehabilitation [11].

While an intensive growth, concerning the craniofacial complex, is characterizing the early childhood and adolescence until the age of 18-20 years, very small but significant changes in this complex are taking place during adulthood [12-31]. The purpose of this study is to investigate these changes of the craniofacial complex in a longterm follow-up over 23 years - the mean age of the patients is 42 to 65 years. After finishing the preprosthetic orthodontic treatment, an exactly examination of the occlusion was performed and necessary grinding of the teeth was done, so long, until a perfect occlusion was obtained. Then the patients became a fixed dental restoration (gold and/or ceramics).

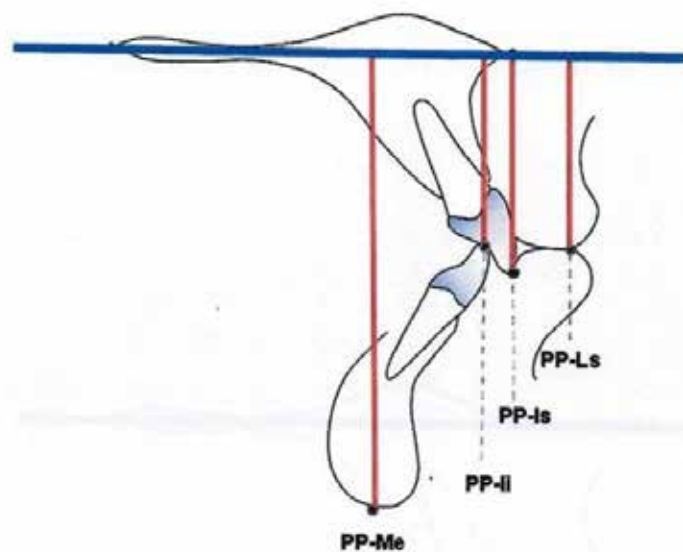
## Materials and Methods

This study was based on lateral cephalometric roentgenograms of individuals who obtained extended dental restorations at the department of preventive and restorative dentistry, Innsbruck Medical University, Austria. Fifteen Austrian patients (13 females and 2 males, mean age 42.04 years, SD 10.05 years) were included in this longitudinal study. The measured craniofacial variables were based on cephalometric reference points and lines shown in Figures 1-3. The measurements were evaluated from cephalograms taken immediately, 10, 15 and 23 years after fixed oral rehabilitation. All cephalometric roentgenograms were traced and distances were manually measured with a digital calliper (Mitutoyo, Tokyo, Japan).



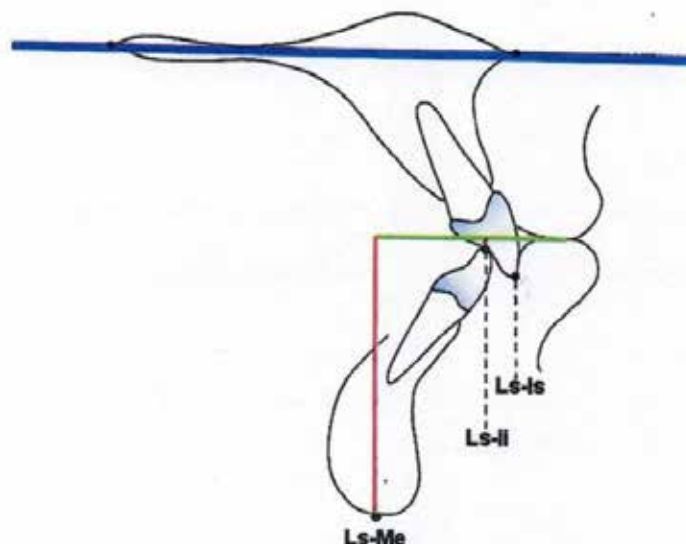
S: Sella; PNS: Spina nasalis posterior; ANS: Spina nasalis anterior; PP: Palatal plane; IP: Individual point; Is: Incisal edge of the upper central incisor; Ii: Incisal edge of the lower central incisor; LS: Lip seal; GOP: Gnathological occlusal plane; Me: Menton; Gn: Gnathion

**Figure 1:** Linear measurement of the distance from Sella to Gnathion



PP-Me: Distance from palatal plane to menton; PP-Ii: Distance from palatal plane to lower central incisor; PP-Is: Distance from palatal plane to upper central incisor; PP-Ls: Distance from palatal plane to lip seal; Blue line: Palatal plane

**Figure 2:** Linear measurements in relation to palatal plane



LS-Me: Distance from lip seal to menton; LS-Is: Distance from lip seal to upper central incisor; LS-li: Distance from lip seal to lower central incisor; Green line: Parallel line to the Palatal plane through the lip seal

Figure 3: Linear measurements in relation to lip seal

All patients attended the oral hygiene program, were diagnosed and initially treated following the guidelines for an updated diagnosis regimen of the masticatory system issued by the ARGE Prothetik und Gnathologie der Österreichischen Gesellschaft für Zahn, Mund- und Kieferheilkunde/Baden 1979 [26]. Several patients needed endodontic, periodontic or orthodontic pre-treatment. After finishing of the preprosthetic treatment and by grinding of the teeth a perfect occlusion of the patients was obtained, a fixed dental restoration (gold and/or ceramic) followed.

### Statistics

Mean values and standard deviations were computed for all variables. As a non-parametric statistical test for the comparison of values obtained from the measurements of radiograms taken immediate, 10, 15 and 23 years after rehabilitation, the Friedman test was applied. Wilcoxon-tests for significant differences between single time-points were performed after a Bonferroni correction for multiple testing. All statistical analyses were performed with SPSS (version 16.0; SPSS Inc).

### Results

Referred to the palatal plane all measured distances showed significant increases except vertical overlap (VOL). The distance from palatal plane to menton (PP-Me) continuously increased from 67.90 mm after cementation to 68.94 mm 10 years, to 69.83 mm 15 years and to 70.57 mm 23 years after fixed rehabilitation (Table 1a). PP-Me showed a total increase of 2.67 mm at the end of the investigated time, which is statistically highly significant (Table 2a).

Parameter	After cementation	After 10 years	After 15 years	After 23 years	p-value
PP-Me	67.90±4.41	68.94±5.58	69.83±4.99	70.57±5.39	<0.001
PP-Is	30.18±2.83	30.67±3.33	31.53±2.91	31.67±2.96	<0.001
PP-li	25.61±2.45	26.05±3.17	26.61±2.68	26.71±3.22	0.024
PP-LS	28.04±2.77	29.04±2.10	30.28±3.15	31.35±3.40	<0.001
PP-IP (%)	100.00±0.00	103.82±5.73	104.68±5.24	105.95±6.06	<0.001
VOL	4.57±1.51	4.62±1.63	4.92±1.33	4.96±1.66	0.027

Table 1a : Distances measured from palatal plane

Parameter	After cementation	After 10 years	After 15 years	After 23 years	p-value
LS-Me	39.64±2.77	39.86±3.3	39.47±3.10	39.01±31.50	0.14
LS-Is	2.14±1.29	1.62±1.52	1.43±1.45	0.32±1.33	<0.001
LS-li	2.43±1.63	2.99±1.76	3.67±1.76	4.64±1.71	<0.001

Table 1b: Distances measured from lip seal

Parameter	After cementation	After 10 years	After 15 years	After 23 years	p-value
S-G	126.73.±6.84	129.04±8.23	130.31±7.97	131.72±8.23	<0.001

Table 1c: Distances measured from Sella to Gnathion

Parameters are given as mean values ± standard deviation

Table 1: Distances measured from various reference points

Parameter	After cementation vs. after 10 years	After cementation vs. after 15 years	After cementation vs. after 23 years	After 10 years vs. after 15 years	After 10 years vs. after 23 years	After 15 years vs. after 23 years
PP-Me	1.04±1.86	1.93±1.42*	2.67±1.66*	0.89±1.91	1.63±1.09*	0.73±1.44
PP-ls	0.48±1.11	1.35±0.92*	1.49±1.16	0.86±0.94	1.00±0.84*	0.14±0.78
PP-li	0.45±1.015	1.00±0.92*	1.10±1.66	0.56±0.86	0.65±0.94	0.09±1.05
PP-LS	1.00±1.13*	2.24±1.52*	3.31±1.68*	1.24±1.09*	2.30±1.12*	1.06±1.03*
PP-IP (%)	3.82±5.73	4.68±5.24*	5.95±6.06*	0.86±3.37	2.12±2.15*	1.27±3.59*
VOL	0.04±0.47	0.35±0.55	0.39±1.03	0.31±0.66	0.35±0.87	0.04±0.86

Table 2a: Distances measured from palatal plane

Parameter	After cementation vs. after 10 years	After cementation vs. after 15 years	After cementation vs. after 23 years	After 10 years vs. after 15 years	After 10 years vs. after 23 years	After 15 years vs. after 23 years
LS-Me	0.22±1.51	-0.17±1.39	-0.63±1.11	-0.39±1.73	-0.84±1.39	-0.46±1.62
LS-ls	0.52±0.68	0.71±1.17	1.82±0.89*	0.19±1.33	1.30±1.06*	1.11±0.97*
LS-li	0.56±0.76	1.24±0.93*	2.21±0.84*	0.68±1.15	1.65±0.84*	0.97±1.31

Table 2b: Distances measured from lip seal

Parameter	After cementation vs. after 10 years	After cementation vs. after 15 years	After cementation vs. after 23 years	After 10 years vs. after 15 years	After 10 years vs. after 23 years	After 15 years vs. after 23 years
S-G	2.31±2.96*	3.58±2.19*	4.99±2.72*	1.27±3.53	2.68±2.75*	1.41±2.29

Table 2c: Distances measured from Sella to Gnathion

Parameters are given as mean values ± standard deviation; na: not available; \*Significant after Bonferroni-correction for multiple testing ( $p < 0.05/6 = 0.008$ )

Table 2: Pairwise differences between time points

The distance from palatal plane to the incisal edge of the central upper incisors (PP-ls) showed a highly significant increase from initial 30.18 mm to final 31.67 mm (accordingly +1.49 mm) 23 years after cementation (Table 1a,2a). The distance from palatal plane to incisal edge of the lower central incisors (PP-li) showed an increase of 1.10 mm 23 years after cementation (Table 2a). The calculated vertical overbite (VOL) therefore increased from initial 4.57 mm to 4.96 mm. This slight increase of 0.39 mm was not statistically significant (Table 1a,2a).

To investigate the changes in the posterior area of the lower jaw we determined an individual point (IP) in the molar region of the mandible of each single patient which could be recognized easily in the lateral cephalometric roentgenograms (disto-buccal cusps of the first molars). The mean values were then expressed in percentages with 100% as the initial value after cementation. The distance from palatal plane to the individual point (PP-IP) increased by 5.95% over 23 years (Table 1a,2a). This change displays a similar tendency we found in the front region (central incisors). The distance from palatal plane to lip seal (PP-LS) increased 3.31 mm 23 years after dental restoration (Table 1a,2a). Whereas the increase of the distance from palatal plane to the lip seal (PP-LS) was highly significant the distance from lip seal to menton (LS-Me) did not change significantly (Table 1b,2b).

The distance from the lip seal to the incisal edge of the upper central incisors (LS-ls) decreased 1.82 mm (Table 1b,2b) and the distance to the incisal edge of the lower central incisors (LS-li) increased by 2.21 mm 23 years after cementation (Table 1b,2b). The length from sella to gnathion (S-G) increased continuously by 2.29 mm after 10 years, 3.64 mm after 15 years and by 4.99 mm after 23 years post cementation. All differences in measurements were statistically significant (Table 1c,2c).

## Discussion

In this study we focused on changes of the vertical craniofacial structures in the lower face and front-teeth and their relationship to their corresponding soft-tissues to evaluate the long term-changes over 23 years after fixed oral rehabilitation with optimized occlusal conditions after the principles of the occlusal concept of sequential guidance with front-canine dominance. Harry Sicher wrote in his paper "The biology of attrition" in 1953: "We must not forget that even in such teeth as the growth, though limited in rate, never stops. The continued and growth of the cementum, and its accentuated increment around the root ends, is a well known fact [32]. "The palatal plane, as a very stable plane, was used as the main reference line for measurements in the present study. Our paper again shows this fact. Our investigation showed that the distance from the palatal plane to the incisal edge of the upper central incisors (PP-ls) increased up to 1.49 mm 23 years after cementation. These findings imply that the upper incisors are undergoing a downward movement perhaps including an enlargement of the vertical dimension of the maxilla. According to these changes the distance from the palatal plane to the incisal edge of the lower central incisors (PP-li) increases 1,10 mm over 23 years after cementation which might be a consequence of the dimensional changes of the maxilla, consequently leading to a slight increase of the vertical overbite (VOL) which was not statistically significant. Several studies showed in their

investigations also an increase in overbite [16,27]. Other longitudinal studies demonstrated in their investigations that no increase of the vertical overbite could be found [22,25,30]. A possible explanation for the stability of the vertical overbite described by other authors may be natural attrition of the teeth of untreated individuals during aging. Our selection of patients obtained the individually best optimal occlusal rehabilitation in order to provide atraumatic function of the stomatognathic system without interference which is supposed to prevent attrition.

The distance from the palatal plane to menton (PP-Me) continuously increased 2,67 mm. The increasing distance from the palatal plane to menton (PP-Me) 23 years after rehabilitation is indicating a continuous downward movement of the upper jaw and lower jaw (meaning a vertical enlargement/"growing" process of the maxilla and mandible and/or eruption of the teeth) is resulting in an increase of the lower facial height. The increase of the lower face height seems to be a natural phenomenon in the adult aging craniofacial complex demonstrated also in several longitudinal studies [23,25,30]. As this observation is in accordance with other studies some authors postulate that the downward movement of the chin and a relative increase of the lower facial height is associated with a posterior rotation of the mandible because of the stability of the gonion-angle [25,30]. Responsible for the posterior rotation of the mandible might be the extrusion of teeth throughout life as a causal factor. Ainamo and Talari showed in their studies that eruption of teeth still occurs in adulthood [33]. Because of the form of nutrition of our forefathers attrition had an essential role to maintain the face height in former times [34]. Nowadays nutritional attrition is less pronounced because of today's nourishment that continuous eruption of teeth may lead to an increase of the lower facial height.

Compared to other studies the present data showed a higher increase of the lower facial height this might be put down to the fact that our occlusal concept is thought to minimize attrition. Another explanation for the increasing lower face height could be a good chewing function. While a toothless jaw leads to bone atrophy a good masticatory function of teeth may stimulate jawbone growth by activating osteoblasts that contributes to the increase of the lower face height. The distance from sella to gnathion (S-G) also continuously increased statistically significant. At the end of the investigated period of 23 years we found an increase of nearly 5mm confirming the downward movement of chin shown in other studies [21-23,25].

Concerning the soft-tissues we found a steady increase of the distance from palatal plane to lip seal (PP-LS) of at least 3,31 mm over the investigated period of time whereas the distance from lip seal to menton (LS-Me) showed no significant change 23 years after cementation. Relating to the soft-tissues the increased lower face height is compensated by an increase of the upper lip-length. These findings coincide with other studies [22,23,25]. Because the age related downward movement of the lip seal happens to a larger amount than those of the upper central incisors the upper front teeth become more and more covered by the upper lip whereas the lower central incisors become more and more uncovered [35-37]. While the soft-tissues are undergoing a continuous change throughout the investigated period the skeletal and dentoalveolar structures are showing rather steadily increasing distances during the first 15 years after fixed dental rehabilitation followed by a tendency of slowing down of the dimensional changes. It seems that the "growth-process" or enlargement of the aging craniofacial complex [19,20]. Continues up to a certain age and then comes to a period of stagnation or even decrease of the craniofacial dimensions [18].

## Conclusion

Significant cephalometric changes in vertical dimensions in the lower face can be measured 23 years after fixed dental rehabilitation without disturbing the stability of the dental restorations [11,5]. These significant changes in the adult lower face should be taken into consideration in prosthetic treatment planning especially when single implants are included in the dental rehabilitation, because of the different behaviour of the implanted jawbone over the years compared to jawbone with natural teeth [32,38].

## References

1. Slavicek R (1984) The functional determinants of the chewing organ. Publisher dental medical literature.
2. Reusch D, Lenze PG, Fischer H (1990) Reconstruction of occlusal surfaces and anterior teeth. Guide for Dentists and Dental Technicians. Westerburger contacts (Rekonstruktion von Kauflächen und Frontzähnen. Leitfaden für Zahnärzte und Zahntechniker. Westerburger Kontakte 1990).
3. Kulmer S, Ruzicka B, Niederwanger A, Moschen I (1999) Incline and length of guiding elements in untreated naturally grown dentition. J Oral Rehab 26: 650-60.
4. Gausch K, Kulmer S, Moser F, Slavicek R (1980) Guidelines of the ARGE Prosthetics and Gnathology for a modern diagnosis of the chewing system. Austrian Dentist Newspaper [Richtlinien der ARGE Prothetik und Gnathologie für eine zeitgemäße Diagnostik des Kausystems. Österr Zahnärztezeitung] 31: 12-16.
5. Kulmer S, Ruzicka B, Stainer M, Niederwanger A (2011) Established prosthodontic rules confirmed in natural adolescent occlusion. J Stomat Occ Med 4: 20-27.
6. Santos DS, Blackman RB, Nelson SJ (1991) Vectorial analysis of the static equilibrium of forces generated in the mandible in centric occlusion, group function, and balanced occlusion relationships. J Prostet Dent 65: 557-67.
7. Shupe RJ, Mohamed SE, Christensen LV, Finger IM, Weinberg R (1984) Effects of occlusal guidance on jaw muscle activity. J Prosthet Dent 51: 811-8.
8. Ott RW, Lechner K-H (1989) Canine guidance and muscular response [Eckzahnführung und muskuläre Reaktion] Dtsch Zahnärztl Z 44: 30-3.
9. D'Amico A (1961) Functional occlusion of the natural teeth of men. J Prosthet Dent 11: 899-915.
10. Solberg WK, Clark CT, Rugh JD (1975) Nocturnal electromyographic evaluation of bruxism patients undergoing short term splint therapy. J Oral Rehab 2: 215-23.
11. Kulmer S, Niedermoser A, Moschen I, Dumfahrt H, Falk M, et al. (1995) Reliability of the cephalometric side view - comparison of the conventional and a computer-assisted evaluation method [Reliabilität des Fernröntgenseitenbildes - Vergleich der konventionellen und einer computerunterstützten Auswertungsmethode] Stomatologie 92/5: 217-23.
12. Enlow DH (1985) Growth of the aging skeleton. University of Michigan 1985.

13. Björk A (1955) Facial growth in man studied with the aid of metallic implants. *Acta Odontol Scand* 13: 9-34.
14. Björk A, Skieller V (1972) Facial development and tooth eruption: an implant study at the age of puberty. *Am J Orthod* 62: 339-83.
15. Björk A, Skieller V (1983) Normal and abnormal growth of the mandible: a synthesis of longitudinal cephalometric implant studies over a period of 25 years. *Eur J Orthod* 5: 50-5.
16. Sarnäs KV, Solow E (1980) Early adult changes in the skeletal and soft-tissue profile. *Eur J Orthod* 2: 1-12.
17. Büchi EC (1950) Changes in body shape in adult humans, a study after the individual method [Änderungen der Körperform bei erwachsenen Menschen, eine Untersuchung nach der Individual-Methode] *Anthropol Forsch* 1:1-44.
18. Lewis AB, Roche AF (1988) Late growth changes in the craniofacial skeleton. *Angle Orthod* 58: 127-35.
19. Israel H (1973) Age factor and the pattern of change in craniofacial structures. *Am J Phys Anthropol* 39: 111-28.
20. Israel H (1973) Recent knowledge concerning craniofacial aging. *Angle Orthod* 43: 176-84.
21. Behrents RG (1985) An atlas of growth in the aging craniofacial skeleton. The University of Michigan Monograph 18.
22. Behrents RG (1985) Growth In The Aging Craniofacial Skeleton. The University of Michigan Monograph 17.
23. Forsberg CM, Odenrick L (1979) Changes in the relationship between the lips and the aesthetic line from eight years of age to adulthood. *Eur J Orthod* 1: 265-70.
24. Forsberg CM (1976) Growth changes in the adult face. Thesis. Faculty of Odontology, Stockholm, Sweden.
25. Forsberg CM, Eliasson S, Westergren H (1991) Face height and tooth eruption in adults - a 20- year follow-up investigation. *Eur J Orthod* 13: 249-54.
26. Bishara SE, Hession TJ, Peterson LC (1985) Longitudinal soft-tissue profile changes: a study of three analyses. *Am J Orthod* 88: 209-23.
27. Bishara SE, Treder JE, Jakobsen JR (1994) Facial and dental changes in adulthood. *Am J Orthod Dentofacial Orthop* 106: 175-86.
28. Bishara SE (2000) Facial and dental changes in adolescents and their clinical implications. *Angle Orthod* 70: 471-83.
29. Formby WA, Nanda RS, Currier GF (1994) Longitudinal changes in the adult facial profile. *Am J Orthod Dentofacial Orthop* 105: 464-76.
30. Bondevik O (1995) Growth changes in the cranial base and the face: a longitudinal cephalometric study of linear and angular changes in adult Norwegians. *Eur J Orthod* 17: 525-32.
31. Kendrick GS, Risinger HL (1967) Changes in the anteroposterior dimensions of the human male skull during the third and fourth decades of life. *Anat Rec* 159: 77-81.
32. Sicher H (1953) The biology of attrition. *Oral Surg Oral Med Oral Pathol* 6: 406-12.
33. Ainamo J, Talari A (1976) Eruptive movements of teeth in human adults. *Colston Papers* 27: 97-107.
34. Murphy T (1959) Compensatory mechanisms in facial height adjustment to functional tooth attrition. *Aust Dent J* 4: 312-23.
35. Vig RG, Brundo GC (1978) The kinetics of anterior tooth display. *J Prosthet Dent* 39: 502-4.
36. Sackstein M (2008) Display of mandibular and maxillary anterior teeth during smiling and speech age and sex correlations. *Int J Prosthodont* 21: 149-51.
37. Van der Geld P, Oosterveld P, Kuijpers-Jagtman AM (2008) Age-related changes of the dental aesthetic zone at rest and during spontaneous smiling and speech. *Eur J Orthod* 30: 366-73
38. Oesterle LJ, Cronin RJ (2000) Adult growth, aging and the single-tooth implant. *Int J Oral Maxillofac Implants* 15: 252-60.