

A Questionnaire on the Awareness and Preference of Wilckodontics among General Dental Practitioners

Abraham J^{1*}, Kumar N¹ and Kishore S²

¹Department of Orthodontics and Dentofacial Orthopedics, Saveetha Dental College, Saveetha University, Chennai, India

²Department of Orthodontics and Dentofacial Orthopedics, SRM Dental College, SRM Institute of Science and Technology, Chennai, India

***Corresponding author:** Abraham J, Post Graduate Student, Department of Orthodontics and Dentofacial Orthopedics, Saveetha Dental College, Saveetha University 162, Poonamalle High Road, Chennai 600077, Tamil Nadu, India, Tel: +917397416891, E-mail: josephkadooparayil@gmail.com

Citation: Abraham J, Kumar N, Kishore S (2020) A Questionnaire on the Awareness and Preference of Wilckodontics among General Dental Practitioners. J Oral Health Dent Sci 4: 201

Article history: Received: 09 June 2020, Accepted: 24 June 2020, Published: 26 June 2020

Abstract

Background: One of the most challenging aspects of orthodontic treatment is its often-prolonged duration. Prolonged treatment poses a burden on the patients and parents, also resulting in pathologic changes (root resorption, periodontal diseases). Accelerated Osteogenic Orthodontics, commonly known as Wilckodontics is the rapid tooth movement followed by decortication. It is a well-documented procedure that is claimed to decrease treatment time by 6 to 9 months of active orthodontic care.

Aim: To investigate the awareness and preference about Wilckodontics among general dental practitioners

Materials and Methods

Study Design: Descriptive Study

Sample Size: 100 dental practitioners were given a questionnaire containing 12 close ended questions related to Wilckodontics

Inclusion Criteria: General dental practitioners (BDS and MDS)

Exclusion Criteria: Dental students

Conclusion: Although dentists have awareness of Wilckodontics and periodontal and surgical treatments which can facilitate speedy alignment, they think patients prefer a more conservative therapy, opting for longer treatment time in lieu of invasive treatment procedures. Efforts should be made on the part of the dentist to alleviate these fears, so to decrease patient treatment time.

Discussion: The long duration of orthodontic treatment remains tedious for the dentist, as well as the patient and the parents. Shortening the duration of treatment might help to prevent pathological sequelae, and increase patient compliance and satisfaction. Studies have shown that both patients and dentists are dissatisfied with the prolonged duration of orthodontic treatment. Treatment can be shortened through physical and biological stimulation, as well as surgical intervention. Any concurrent treatment, however, should be safe for the patient. In order to provide the best possible care, it is important for the dentist to be aware of the various treatments available to reduce treatment time. This study confirms awareness of the practicing dental population to the various adjunctive procedures used in orthodontics.

Keywords: Wilckodontics; Awareness; Treatment Duration; AOO; Surgically Assisted Orthodontics

Introduction

The wilckodontics accelerated Osteogenic Orthodontics (AOO) procedure is a powerful interdisciplinary (surgical and orthodontic technique). [1-7] that can make the treatment of a very complicated scenarios more routine, make the treatment of routine cases extremely fast and predictable and provide a new 'orthodontic patient population' for the practitioner. The AOO treatment instead focuses on enhancing the manner in which the periodontium responds to applied forces and on providing for a more intact periodontium and increased alveolar volume to support the teeth and overlying soft tissues in retention. The surgical component of the AOO technique is an in-office procedure. The post-operative recovery should be no more comfortable than that of other orthodontic-related surgeries, such as third molar removal, bicuspid extraction, exposures and gingival grafting, and it is certainly less of an issue than the recovery following orthognathic surgery.

The cascading physiological response was consistent with the regional acceleratory phenomenon (RAP) as initially reported by Frost [8] in endochondral long bones and later by Yaffe, *et al.* [9] in the membranous bones of jaws. The metabolism in the healing response was thus accelerated in both the hard and soft tissues of the periodontium and when synthesized with the periodontal tissues engineering principles of enhanced clot stabilization around particulate bone grafting material provided for orthodontic tooth movement (OTM) 300 to 400 percent faster, increases in the envelope of motion (degree of movement) two- to three-fold, and an increased alveolar volume for more stable clinical outcomes and subtle facial morphing.

The AOO technique stems from an innovative interpretation of surgically stimulated tooth movement and simultaneous alveolar augmentation. In synthesizing emerging concepts in cellular and molecular biology Murphy [10] has referred to the ability to morph bone with orthodontic tooth movement done in conjunction with periodontal bone activation and alveolar augmentation as “*in vivo* tissue engineering.” The AOO treatment creates a four- to five-months “window of opportunity” that provides more than enough time to accomplish the major tooth movement when the correct protocols are used. To accommodate the physiological realities of the different aspects of the AOO treatment, the orthodontist must utilize a very different set of diagnostic and treatment planning parameters.

Rudimentary surgical intervention to speed tooth movement has been used in various forms for more than a hundred years. Heinrich Kole’s publication in 1959 [11] however, laid the foundation for subsequent evolution in de-cortication facilitated orthodontics. It was Heinrich Kole’s belief that the continuity of the denser cortical bone offered the greatest resistance to tooth movement. He theorized that by disrupting the continuity of the cortical layers of bone with corticotomy surgery the outlined segments of bone containing one or more teeth could be readily moved with traditional orthodontic forces since they would only be connected by less dense medullary bone. From Kole’s work arose the term “bony block movement.” to describe the suspected mode of tooth movement subsequent to corticotomy surgery. Over the next 40 years, many variation of Kole’s technique were reported but the facilitated tooth movement in all these techniques continued to be attributed to “bony block movement” [12-15].

In 2001, however, Wilcko, *et al.* [3] challenged the concept of “bony block movement.” They reported that in an evaluation of corticotomized patients, utilizing hospital-based high resolution CT scan imaging, that the small blocks of outlined bone lose their structural integrity due to some apparent demineralization of the alveolar housing over the root prominences. The luxation of the teeth or any outlined single-tooth segment of bone in a single-stage surgery (reflection of both facial and lingual flaps) is absolutely contraindicated and can result in intrapulpal and intraosseous morbidity. “Green stick fracturing” and luxation of small dentoalveolar segments will not serve a useful purpose since these segments will quickly lose their structural integrity as a result of the demineralization process. The bone activation results in increased tissue turnover and a transient demineralization of the alveolar housing, the degree of which is directly commensurate with the intensity and proximity of the surgical insult. This demineralization of the alveolar housing occurs due to an increase in the number of osteoclasts and in the absence of hyalinization necrosis and indirect resorption of infection will leave behind the soft tissue matrix of the bone. The demineralization is a prostaglandin mediated sterile inflammatory process [16].

The response of the bone activation is very limited and will only occur with very close approximation to the osseous insult. For example, bone activation on the facial surface of the alveolus will not provide for significant demineralization on the lingual of the alveolus. A thin layer of highly reactive bone is very conducive to tooth movement. The opposite of this, a thicker layer of relatively quiescent bone, would thus favour post-treatment stability [16,17]. In short, the corticotomy procedure is as follows. Initial sectional corticotomy followed by the occurrence of osteopenia where the mineral content is temporarily reduced. The next 20 – 55 days is followed by mineralisation of new bone. The following transient stage is the formation of softer bone, where it imparts lesser resistance to force and that allows rapid realignment of the teeth [18,19]. The aim of this questionnaire was to investigate the awareness and preference about Wilckodontics among general dental practitioners.

Materials and Methods

This study is a descriptive study which contained 12 close ended questions related to wilckodontics and the take on this procedure among orthodontists. 100 random dental and orthodontic practitioners were given this questionnaire in a printed format. The inclusion criteria were both graduates and post-graduate practitioners while the students were excluded from the study. The close ended questionnaire was analysed and the answers were tabulated and frequency chart and tables were calculated using the SPSS software, Microsoft 2000 version©.

The questions included in the questionnaire are as follows: Table 1

- | |
|---|
| <ol style="list-style-type: none"> 1) How often do you handle patients with malocclusion in your practice? <ol style="list-style-type: none"> a. 50 patients annually b. 100 patients annually c. More than 100 patients 2) Preferred method of orthodontics? <ol style="list-style-type: none"> a. Removable b. Fixed |
|---|

- 3) Average duration of treatment?
 - a. Less than 6 months
 - b. 6-9months
 - c. 9-12 months
 - d. More than 12 months
- 4) Preference regarding duration:
 - a. From patients perspective-
 - i. Shorter (<4- 9months)
 - ii. Longer (>9months)
 - b. From Clinician/Specialists perspective
 - i. Shorter (<4- 9months)
 - ii. Longer (>9months)
- 5) Opinion regarding surgically assisted orthodontics?
 - a. From patients perspective-
 - i. Preferable
 - ii. Non preferable
 - b. From Clinician/Specialists perspective
 - i. Preferable
 - ii. Non preferable
- 6) Do you think an extraction space closure can be accelerated by surgically removing a part of the cortical bone in the edentulous area?
 - a) Yes
 - b) No
- 7) What do you think would increase the time taken for space closure?
 - a) Delay in the rate of resorption of vertical bone
 - b) Delay in the rate of resorption of medullary bone
- 8) Do you think that the above mentioned method of extraction space closure can give rise to unwanted complications?
 - a) Yes
 - b) No
- 9) Have you heard of the above mentioned method which is also known as Wilckodontics or Accelerated Osteogenic Orthodontics (AOO)?
 - a) Yes
 - b) No
- 10) Do you think Accelerated Osteogenic Orthodontic surgical treatment would bring about abrupt changes to the facial profile of the patient as compared to the conventional orthodontic treatment?
 - a) Yes
 - b) No
- 11) Do you think AOO is comparatively more painful than the conventional space closure orthodontic treatment?
 - a) Yes
 - b) No
- 12) The incidence of relapse post treatment is more in
 - a) Conventional fixed orthodontic treatment
 - b) Surgically treated orthodontic treatment

Results

There were 100 participants in this descriptive study and among them, 33.3% were general practitioner, 36.7% were oral surgeons and the remaining 30% of them were orthodontists, as shown in Figure 1. Among the 100 participants, 46.7% of them handle 50 patients with malocclusion annually, and another 46.7% of them handle 100 patients with malocclusion annually while only 6.7% of them handle more than 100 patients with malocclusion annually, as shown in Figure 2. 98.3% of the practitioners prefer rendering fixed orthodontic treatment over removable. 18.3% of the practitioners think the average duration of the treatment would ideally be around 9 months, while 41.7% of them think it would be around 12 months, and the rest 40% of them think it would be for more than 12 months. From the patients perspective of it, the practitioners think the patients would prefer a shorter duration of treatment time, while from the clinicians point of view, they think longer duration of treatment rendered, more than 9 months would be more ideal in terms of retention and stability.

When coming to the opinion with regard to surgically assisted orthodontics, 100% think the patients wouldn't prefer it, while 98.3% of the practitioners also find it non-preferable. All practitioners agree upon the fact that the extraction space closure can be accelerated by surgically removing a part of the cortical bone in the edentulous area. 30% of the practitioners think due to the delay in the rate of resorption of vertical bone, there is an increase in the time taken for space closure, while 70% of the practitioners think it is due to the delay in the rate of resorption of the medullary bone. 53.3% of the practitioners think surgically assisted orthodontic treatment could give rise to unwanted complications. While 38.3% of the practitioners are not aware of the method wilckodontics. 50% of the practitioners also think AOO brings about changes in the facial profile while compared to the conventional orthodontic treatment. While 50% of the practitioners also think AOO is more painful than conventional orthodontic treatment. All the practitioners agree upon the factor that the incidence of relapse post conventional fixed orthodontic treatment is more when compared to a surgically assisted orthodontic treatment, as explained in Figure 3.

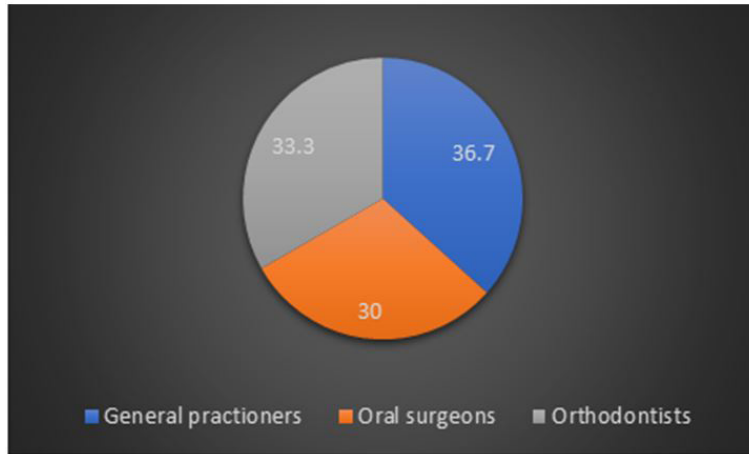


Figure 1: Percentage in the various field of practitioners

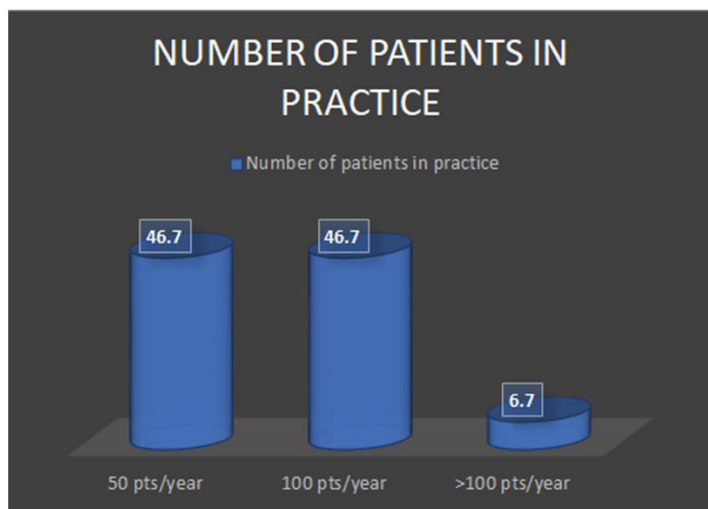


Figure 2: Number of patients the practitioners treat annually

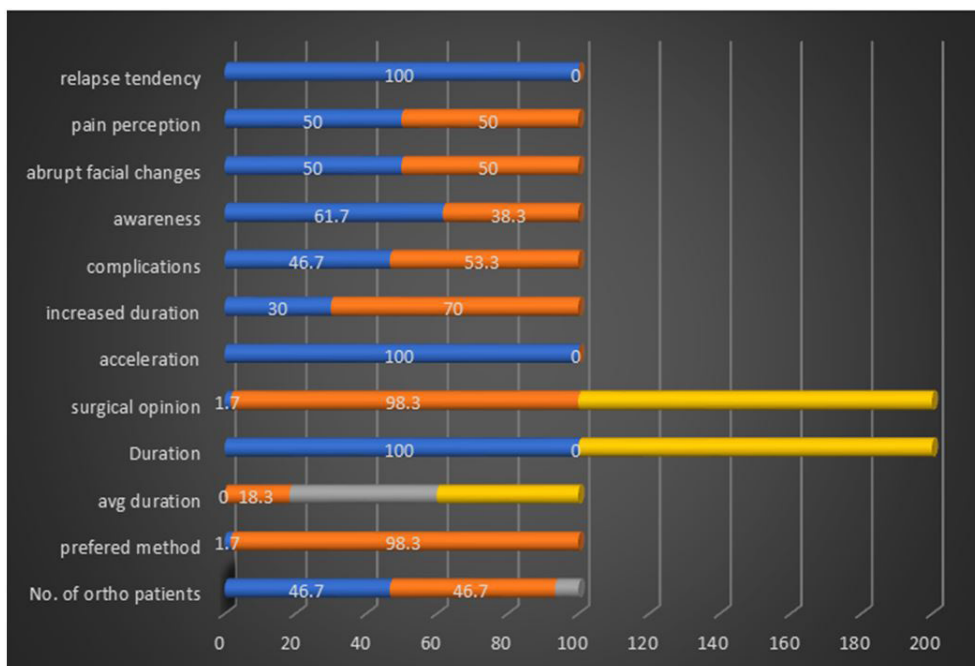


Figure 3: Frequency chart table of the questionnaire, self-explanatory of the answers given by the 100 participants on the 12 close ended questions

Discussion

The long duration of orthodontic treatment remains tedious for the dentist, as well as the patient and the parents. Shortening the duration of treatment might help to prevent pathological sequelae, and increase patient compliance and satisfaction. Studies have shown that both patients and dentists are dissatisfied with the prolonged duration of orthodontic treatment. Treatment can be shortened through physical and biological stimulation, as well as surgical intervention. Any concurrent treatment, however, should be safe for the patient. In order to provide the best possible care, it is important for the dentist to be aware of the various treatments available to reduce treatment time. This study confirms awareness of the practicing dental population to the various adjunctive procedures used in orthodontics. The accelerated osteogenic orthodontic technique can provide the trained general practitioner or the specialist with the ability to accomplish comparatively faster treatments in an in-office setting that would have previously not been a consideration [16,17, 20-22].

The study also shows that, the practitioners awareness level of this AOO treatment protocol is relatively lower, hence the inhibition of using this treatment plan for the patients. While in severe cases of malocclusion this method is more preferred for the reduction in the treatment time. It is fair to say that, more awareness of this treatment protocol is required, it is equally beneficial for the patient and the practitioner. Also, awareness among the patients with respect to the treatment plan, the pros and cons, the benefits about this technique is still required. With the increase in the popularity of this method, gaining awareness would be beneficial [23].

Conclusion

Although dentists have awareness of Wilckodontics and periodontal and surgical treatments which can facilitate speedy alignment, they think patients prefer a more conservative therapy, opting for longer treatment time in lieu of invasive treatment procedures. Efforts should be made on the part of the dentist to alleviate these fears, so to decrease patient treatment time. The AOO treatment should not be considered as a rescue technique or a treatment of last resort. The AOO technique can provide the trained practitioner with the ability to accomplish treatments in an in-office setting that would have previously not been a consideration.

References

1. MT, Wilcko WM, Bissada NF (2008) An evidence-based analysis of periodontally accelerated orthodontic and osteogenic techniques: A synthesis of scientific perspectives. *Semin Orthod* 14: 305-16.
2. Wilcko MT, Wilcko WM, Pulver JP, Bissada NF, Bouguot JE (2009) Accelerated osteogenic orthodontics technique: a 1-stage surgically facilitated rapid orthodontic technique with alveolar augmentation. *J Oral Maxillofac Surg* 67: 2149-59.
3. Wilcko WM, Wilcko MT, Bouquot JE, DJ Ferguson (2001) Rapid orthodontics with alveolar reshaping: two case reports of decrowding. *Int J Periodontics Restorative Dent* 21: 9-19.
4. Wilcko WM, Ferguson DJ, Bouquot JE, Wilcko T (2003) Rapid orthodontic decrowding with alveolar augmentation: case report. *World J Orthodont* 4: 197-505.
5. Wilcko MT, Wilcko WM, Breindel Omniewski K (2009) The periodontally "accelerated osteogenic orthodontics "technique (PAOO)" technique: Efficient space closing with either orthopedic or orthodontic forces. *J Implant Adv Clin Dent* 1: 45-68.
6. Ferguson DJ, Wilcko WM, Wilcko MT (2006) Selective alveolar decortication for rapid surgical-orthodontic resolution of skeletal malocclusion treatment, in Bell WE, Guerrero C (eds): *Distraction Osteogenesis of Facial Skeleton*. Hamilton, BC, Decker pp. 199-203.
7. Wilcko MT, Wilcko WM, Marquez MG (2007) Chapter 4: The contributions of periodontics to orthodontic therapy, in Dibart S (ed): *Practical Advanced Periodontal Surgery*. Ames, IA, Wiley Blackwell pp. 25-50.
8. Frost HM (1989) The biology of fracture healing. An overview for clinicians. Part 1, *Clin Orthop Rel Res* 248: 294-309.
9. Yaffe A, Fine N, Binderman I (1994) Regional acceleratory phenomenon in the mandible following mucoperiosteal flap surgery. *J Periodontal* 65: 79-83.
10. Murphy NC (2006) *In vivo* tissue engineering for orthodontists: a modest first step, in Davidovitch Z, Mah J, Suthanarak S (eds): *Biological Mechanisms of Tooth Eruption, Resorption and Movement*. Boston, Harvard Society for the Advancement of Orthodontics pp. 385-410.
11. Köle H (1959) Surgical operations of the alveolar ridge to correct occlusal abnormalities. *Oral Surg Oral Med Oral Pathol* 12: 515-29.
12. Suya H (1991) Corticotomy in orthodontics. In: Hösl E, Baldauf A (Eds). *Mechanical and Biological Basics in Orthodontic Therapy*. Heidelberg, Germany, Hütlig Buch pp. 207-26.
13. Anholm M, Crites D, Hoff R, Rathbun E (1986) Corticotomy-facilitated orthodontics. *Calif Dent Assoc J* 14: 7-11.
14. Gantes B, Rathbun E, Anholm M (1990) Effects on the periodontium following corticotomy-facilitated orthodontics. Case reports. *J Periodontal* 61: 234-8.
15. Generson RM, Porter JM, Zell A, Stratigus GT (1978) Combined surgical and orthodontic management of anterior open bite using corticotomy. *J Oral Surg* 36: 216-9.
16. Sebaoun JD, Ferguson DJ, Wilcko MT (2007) Corticotomy. Alveolar and rapid orthodontic treatment (Corticotomie. Alvoilaire et traitements orthodontiques rapides). *Orthod Fr* 78: 217-25.
17. Little RM (1993) Stability and relapse of dental arch alignment, in Burstone CJ, Nanda R (eds): *Retention and Stability in Orthodontics*. Philadelphia, Saunders pp. 97-106.
18. Rothe LE, Bollen RM, Herring SW, Robert M Little, Jeremy B Chaison, Curtis SK Chen, et al. (2006) Trabecular and cortical bone as risk factors for orthodontic relapse. *Am J Orthod Dentofacial Orthop* 130: 476-84.
19. Fuhrmann R (2002) Three-dimensional evaluation of periodontal remodeling during orthodontic treatment. *SeminOrthod* 8: 23-28.
20. Machado IM, Ferguson DJ, Wilcko WM, et al. (2002) Root resorption after orthodontic treatment with or without alveolar corticotomy. (Reabsorción radicular después del tratamiento ortodóncico con o sin corticotomía alveolar). *Rev Ven Ort* 19: 647-53.
21. Narayanan M, Arun C (2015) Management of anaphylaxis in dental office – An update. *ARPN Journal of Eng Appl Sci*10(3).
22. Padma A, Ramakrishnan N, Narayanan V (2007) Management of patients on oral anti-coagulant therapy undergoing dental surgical procedures. *Indian J Dent Res* 18(4).
23. Ashfaq Ahmed M, Abilasha (2016) Dental arch measurements. *J Pharma Sci Res* 8: 1199-201.